

CLINICAL CASE I

IMMEDIATE IMPLANTATION

using the Hexacone® system
on a maxillary central incisor

Abstract

Chief complaints

- Pain and mobility on the maxillary right central incisor
- Esthetic failure of the anterior upper block

This clinical case describes the extraction of a fractured right maxillary central incisor tooth, on a 46 y. o. female, followed by the immediate placement of a dental implant in the prepared socket and temporization of the upper anterior block.

The tooth was atraumatically extracted, the socket was prepared to the required depth and a Hexacone® implant was inserted.

The precise operating technique and the immediate insertion of the implant in addition to the provisional restauration resulted in the preservation of the hard and soft tissues at the extraction site while providing the patient with immediate esthetics, function & comfort.

The surgery was performed by Dr. Ralph Zarazir, using the Hexacone® system

INTRODUCTION

Dr. Ralph F. Zarazir
DDS, MDS, MSc, DRED

Member of the national dental board
Beirut - Lebanon



Ralph is an oral surgeon from Lebanon, specialist in dental implantology. He also holds a university diploma in restorative/esthetic dentistry and another master degree in medical sciences.

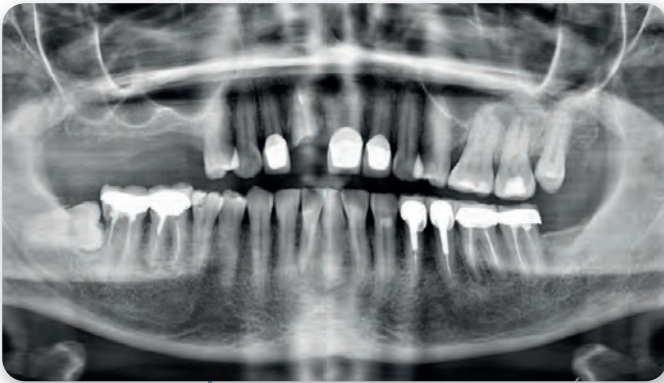
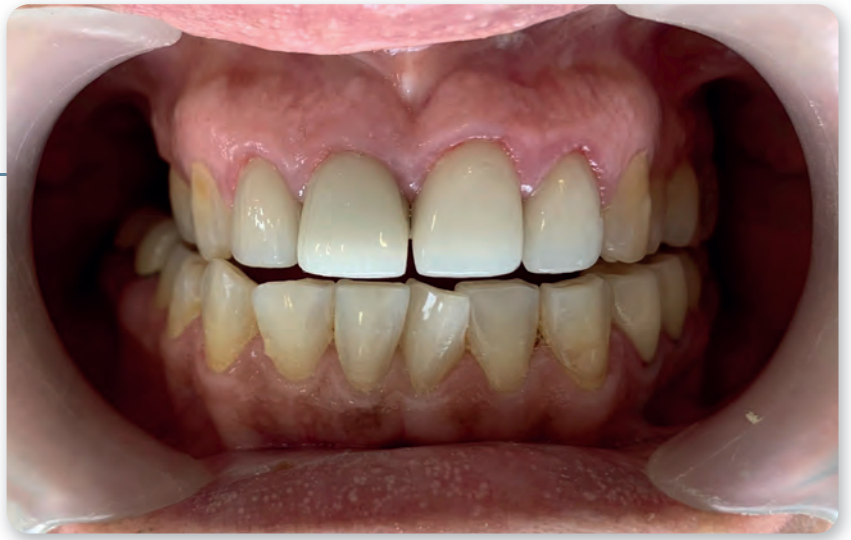Dr. Zarazir is a senior lecturer at the St. Joseph university and actually working on his PhD.

He enjoyed visiting more than 90 countries; meeting different people while discovering new places and spreading good education in dentistry & medicine with ethics is one of his favorites in life.

1

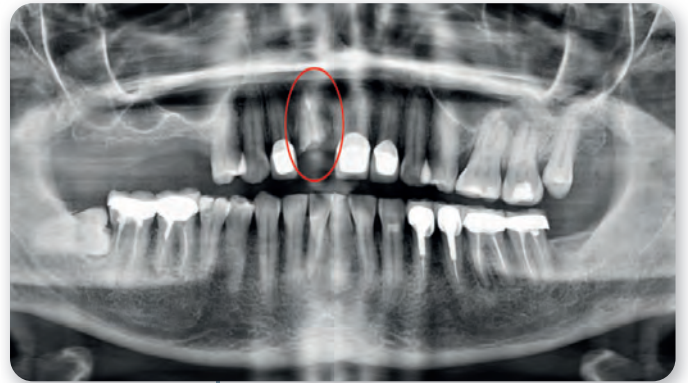Broken maxillary central incisor

Esthetic failure of the upper anterior block



2

Panoramic radiography

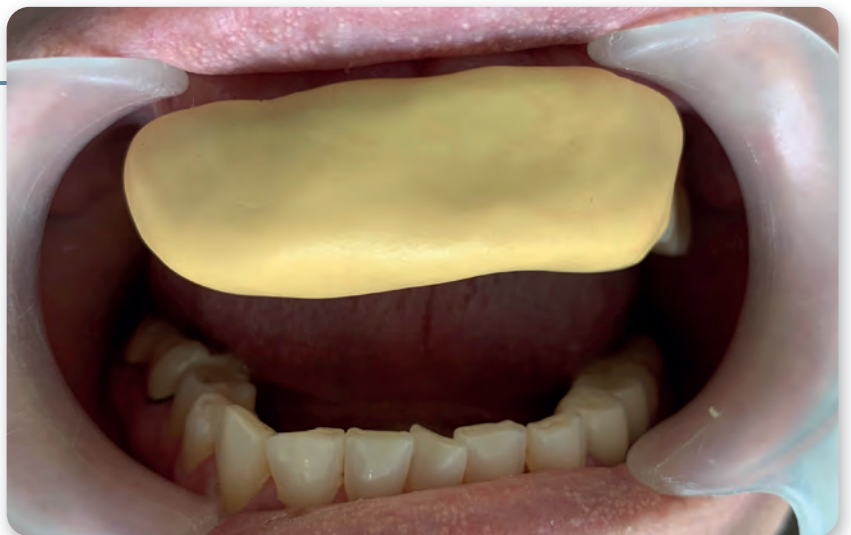

3

The broken central

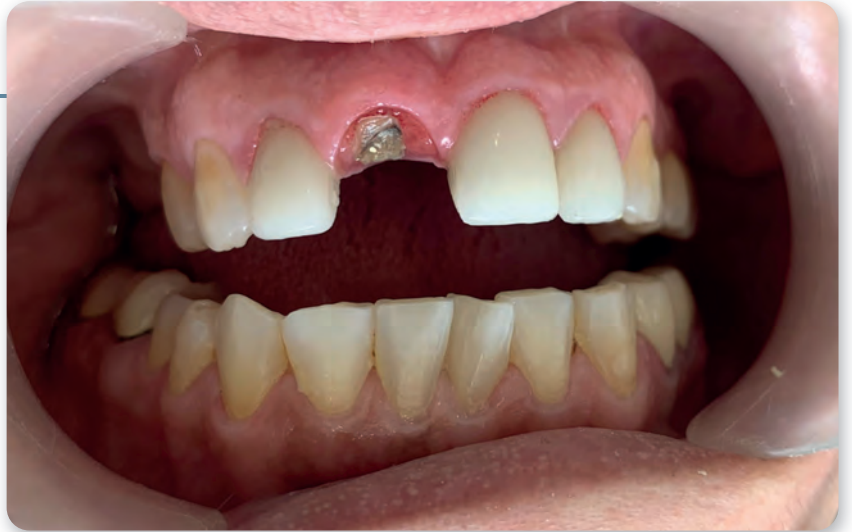4

Silicon key for temporaries



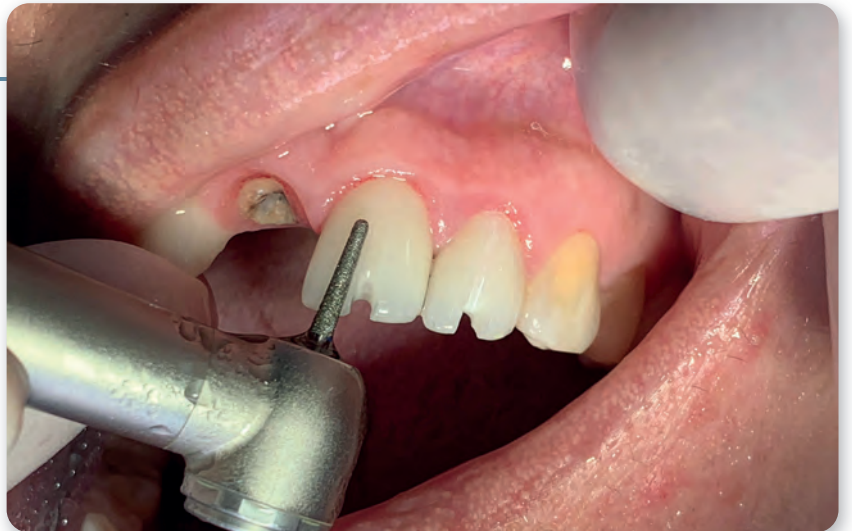5

Crown removal & cleaning
of cement remnants



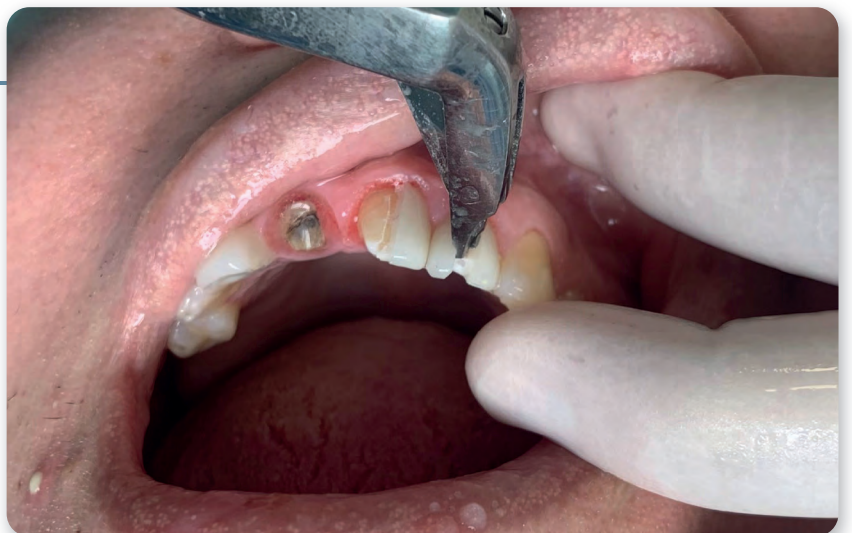6

Ceramic crowns sectioning



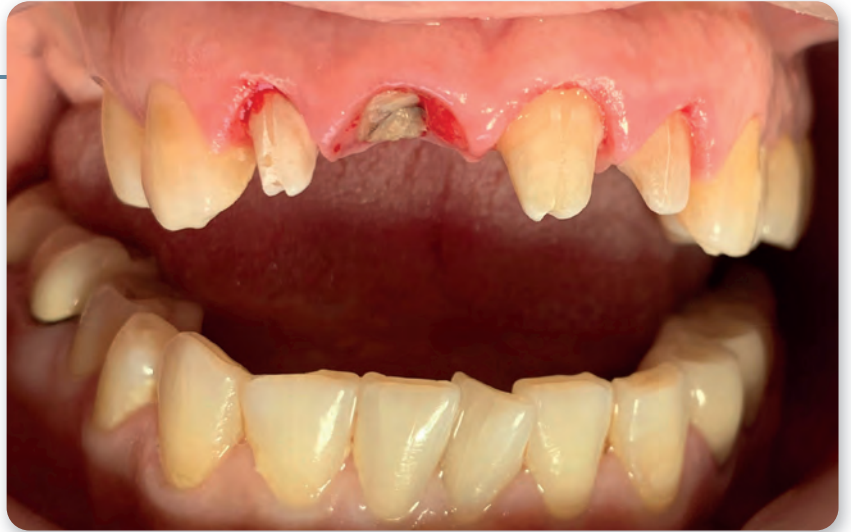7

Elimination of the crowns



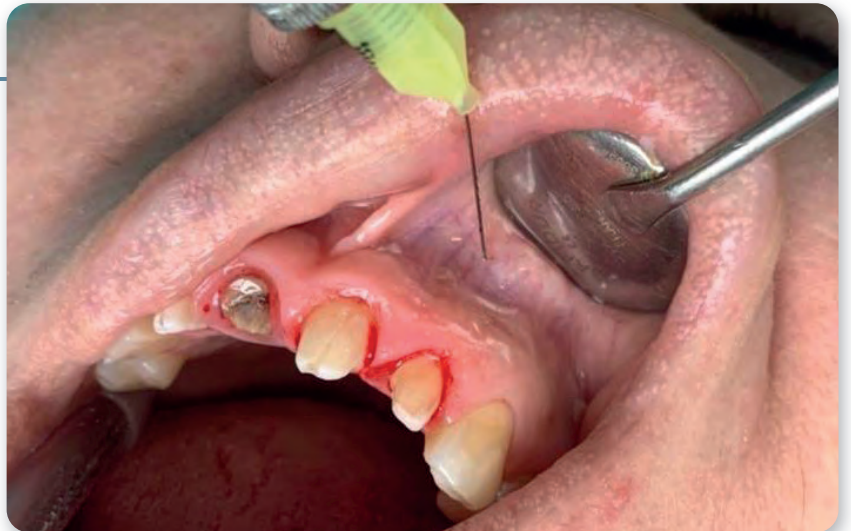8

Cement cleaning



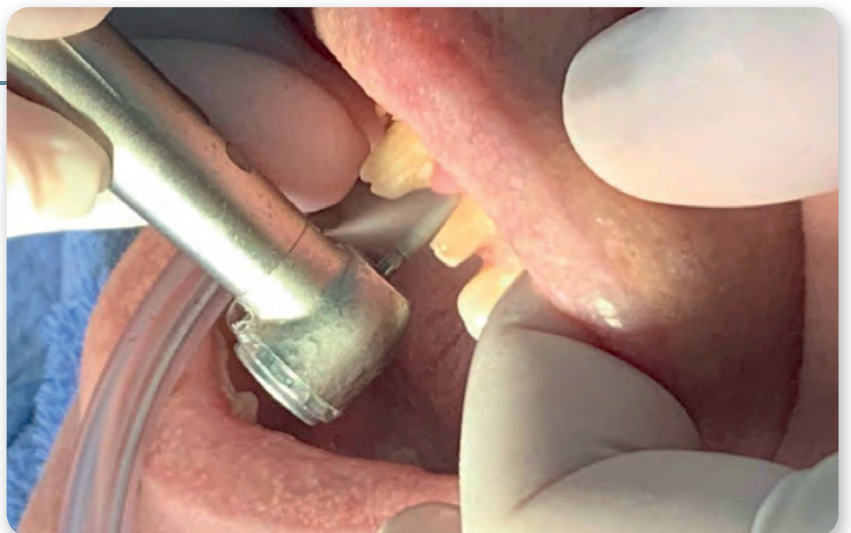
9

Local anesthetics



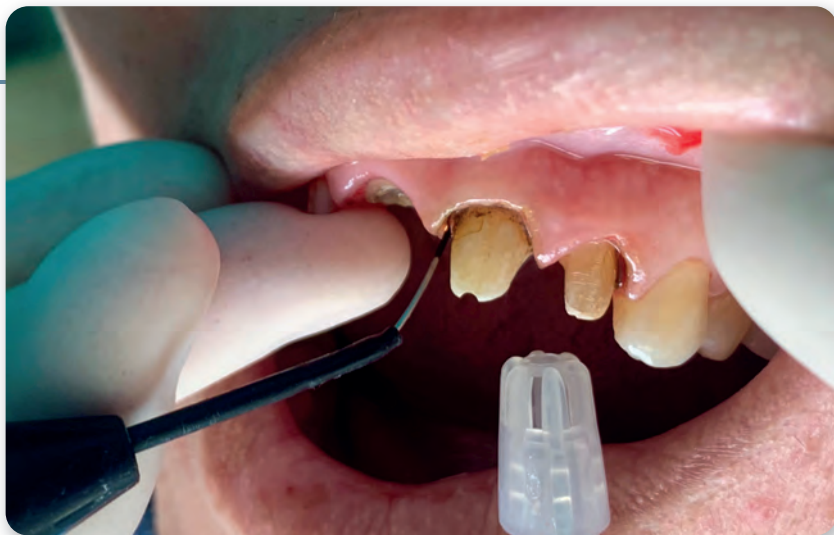10

Prosthetic preparation



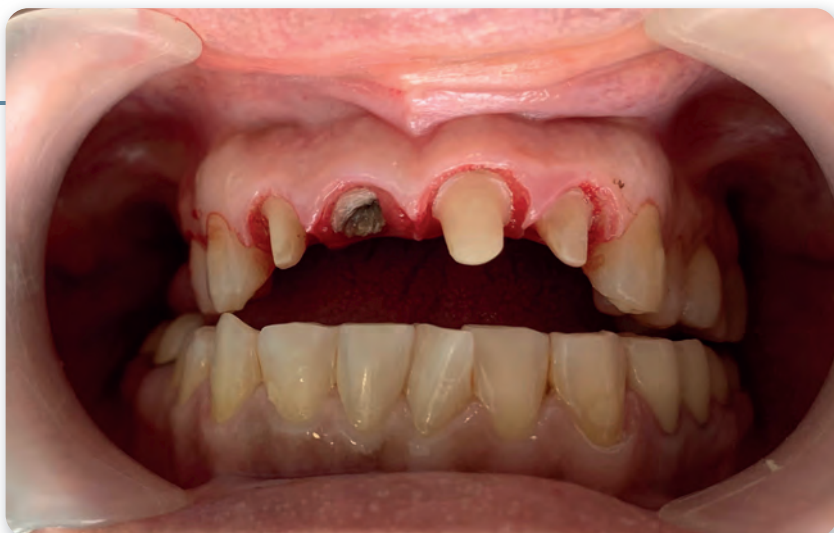11

Soft tissue management




12

Final prosthetic preparation & polishing



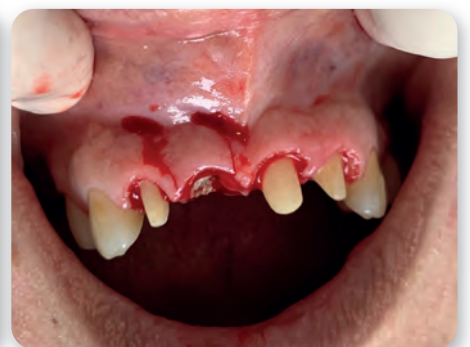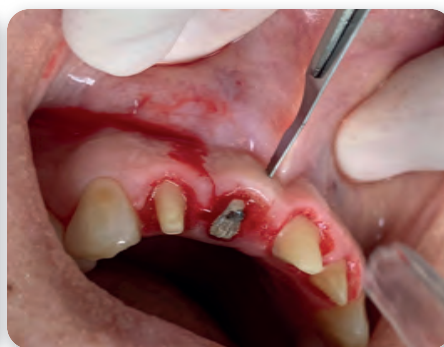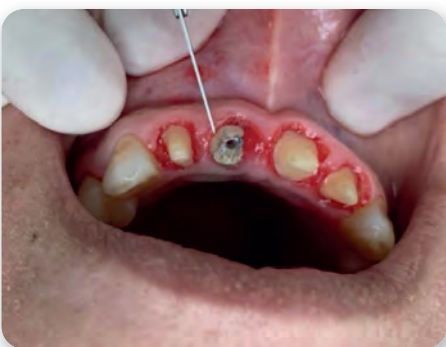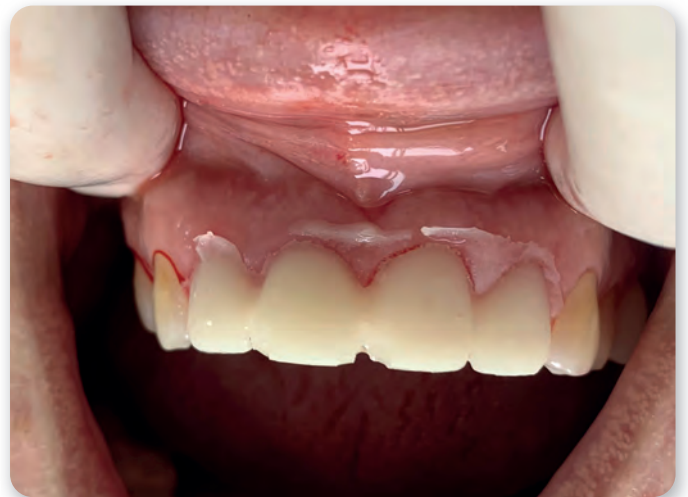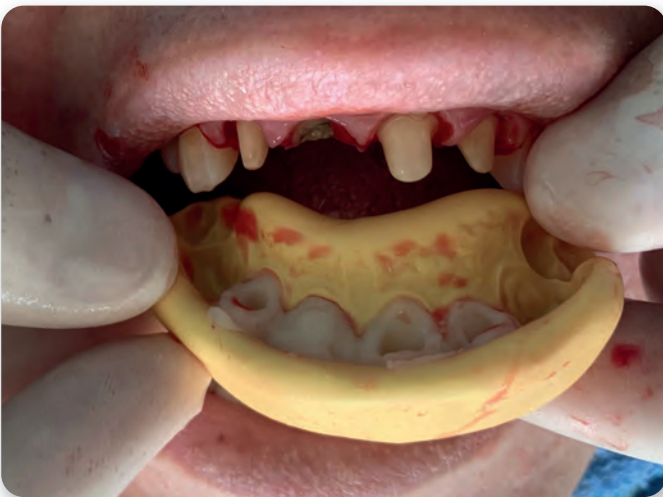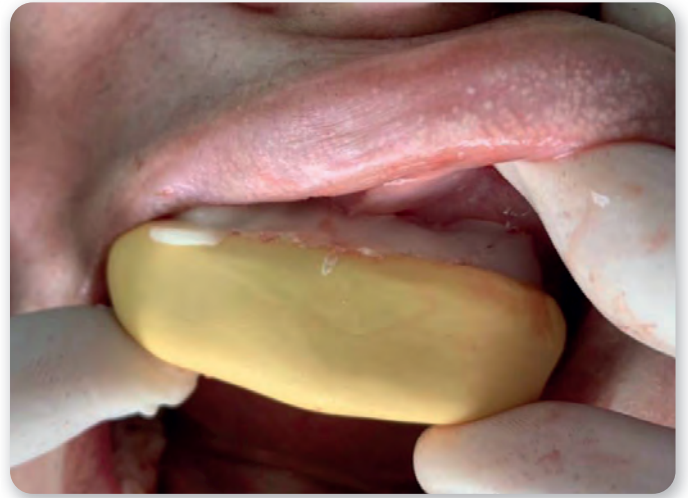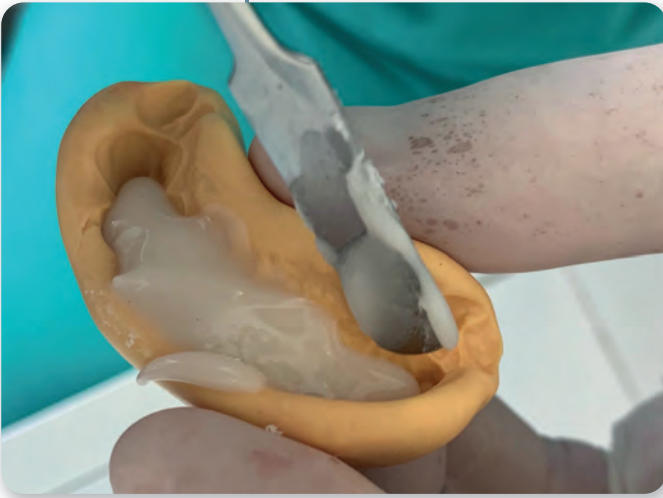IMPLANT DENTISTRY



MADE SIMPLE

13 - 16

Temporaries

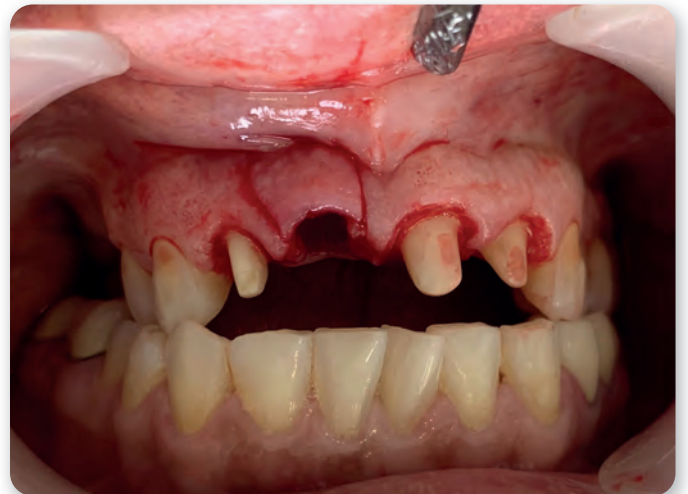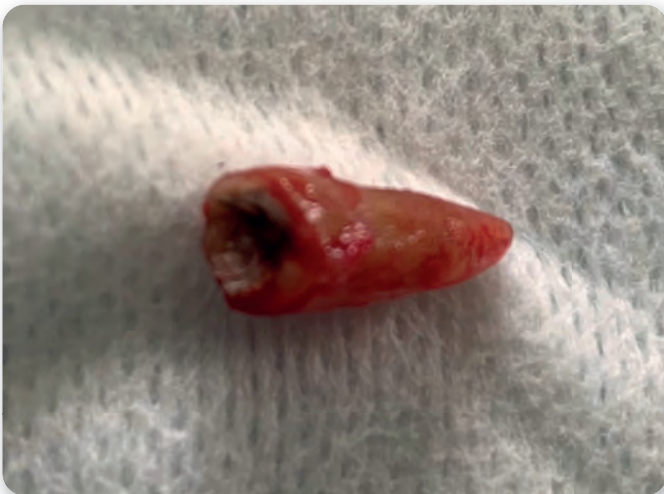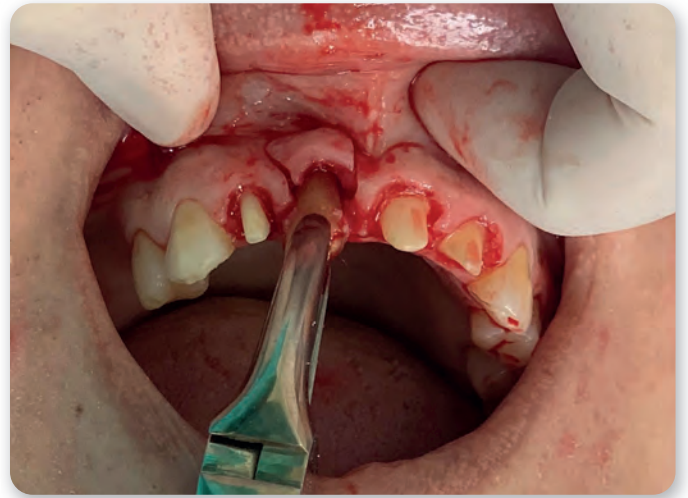


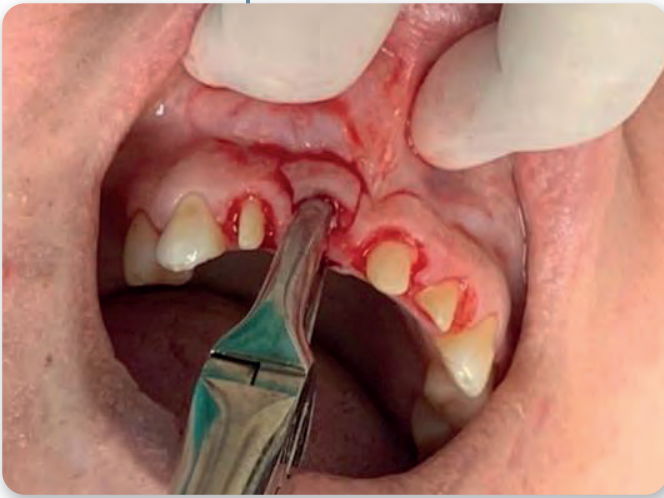17 - 19

Papilla preservation incision

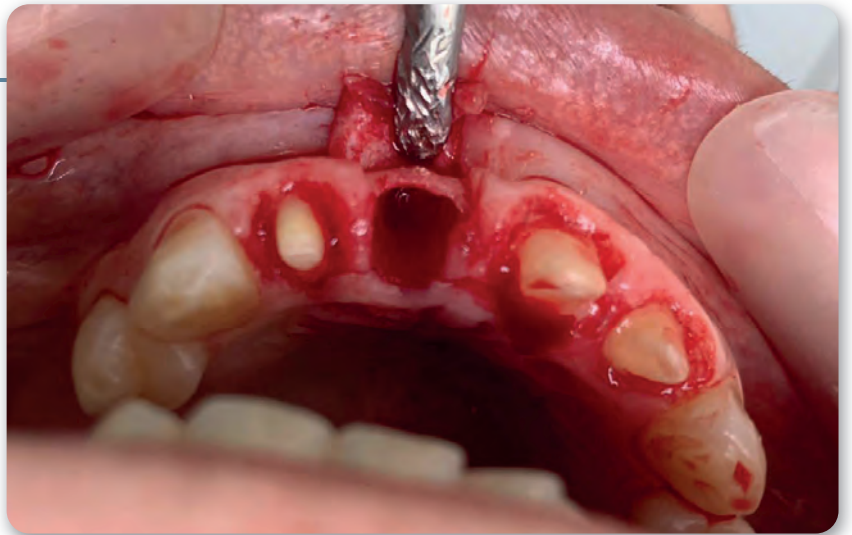20 - 23

Atraumatic tooth
extraction



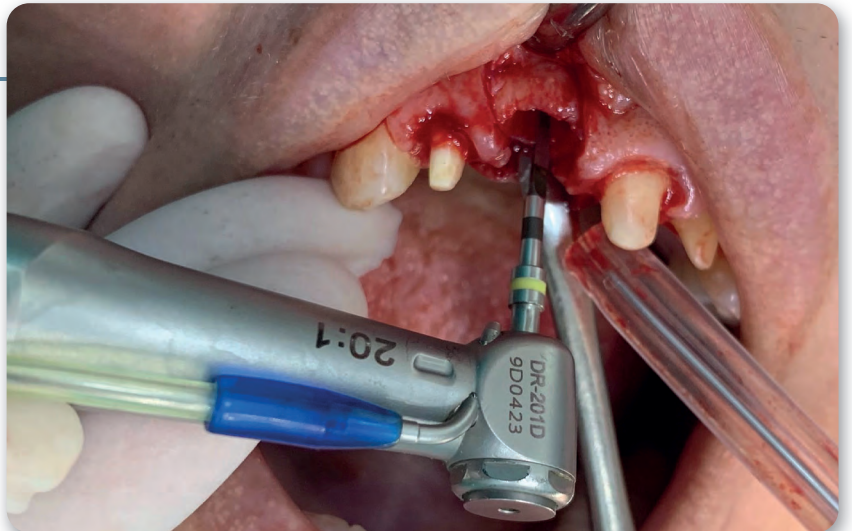
24

Minimal flap elevation



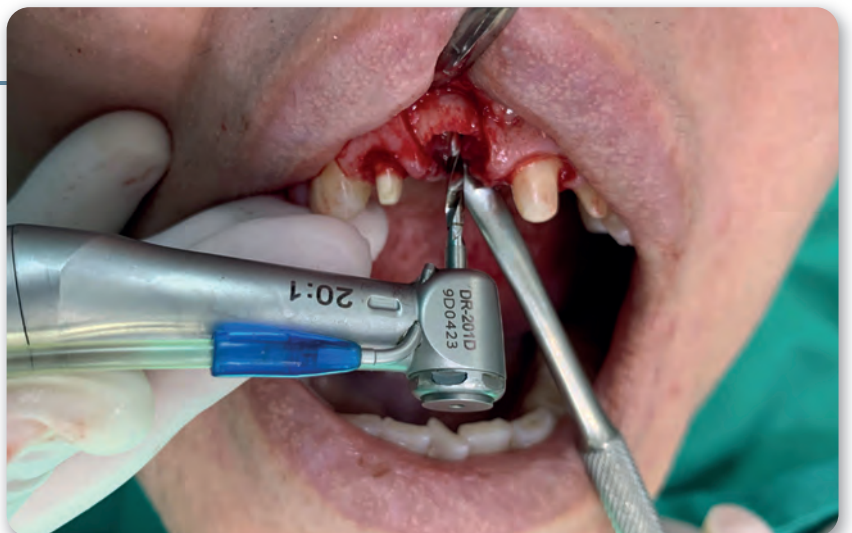25

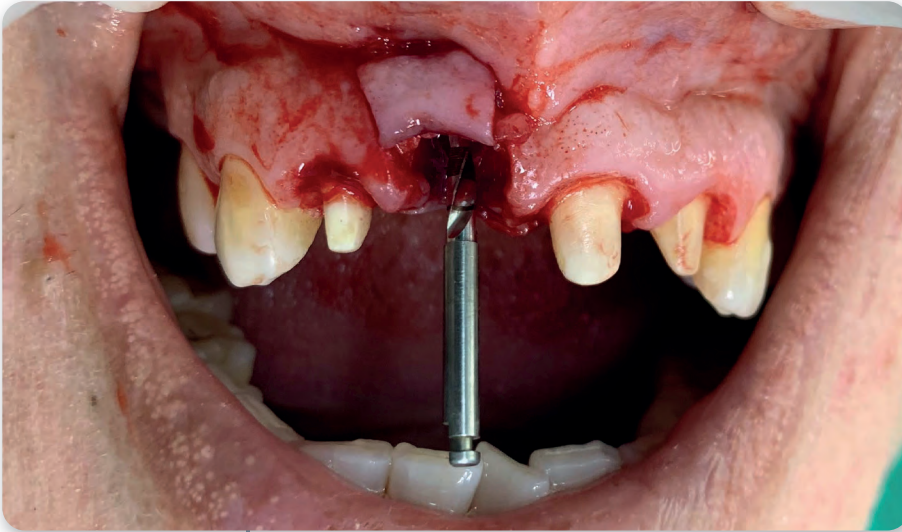
Pilot drill



26

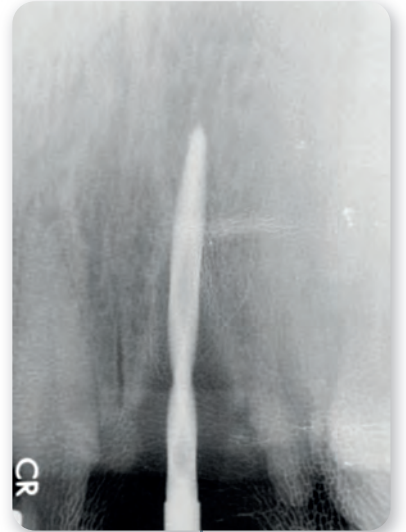Drill 1





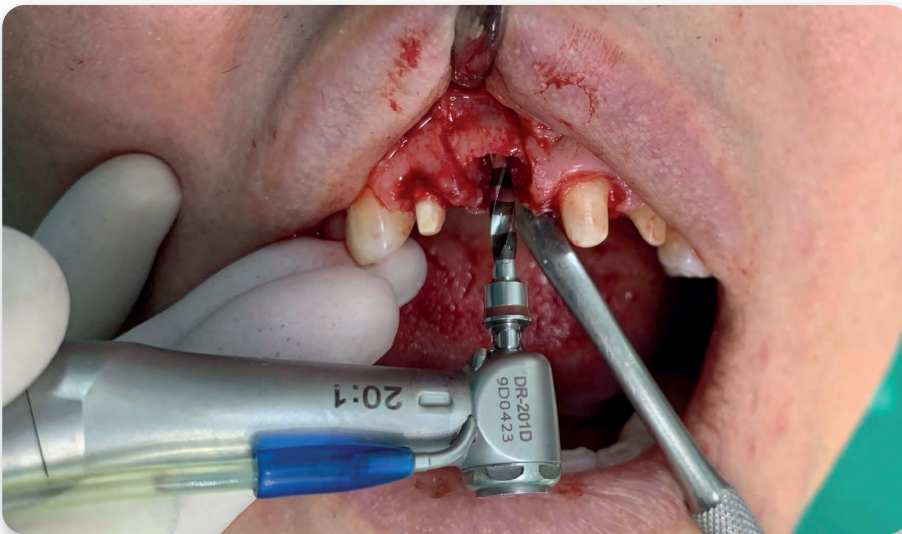27

Drill 2



28

Radiographic check

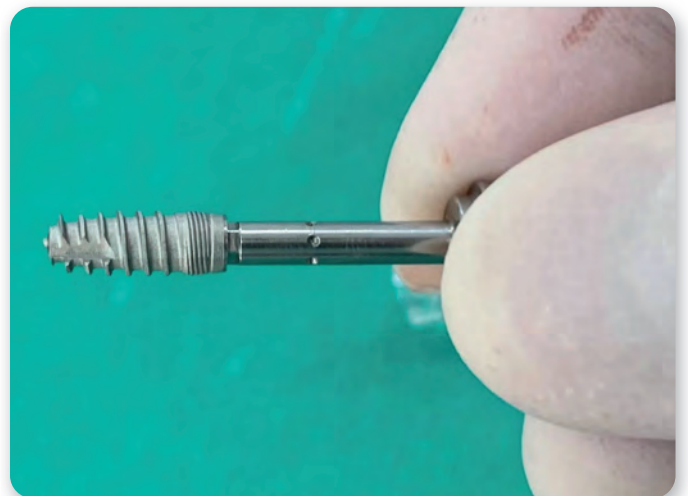
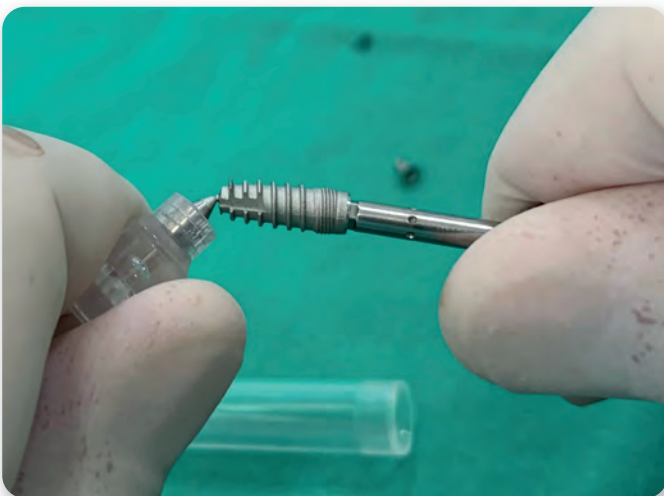
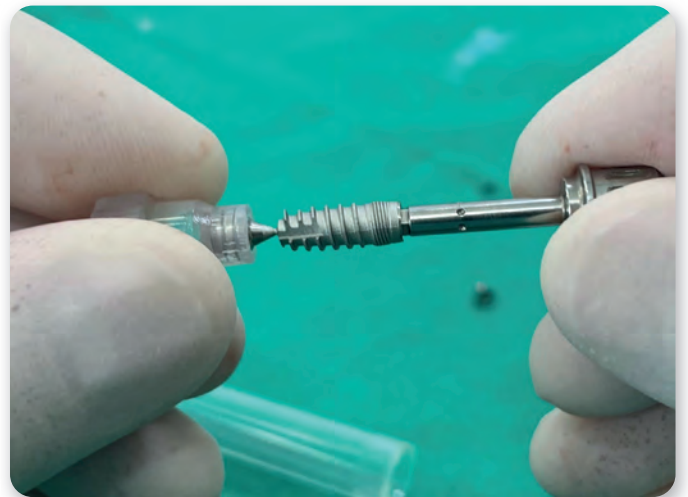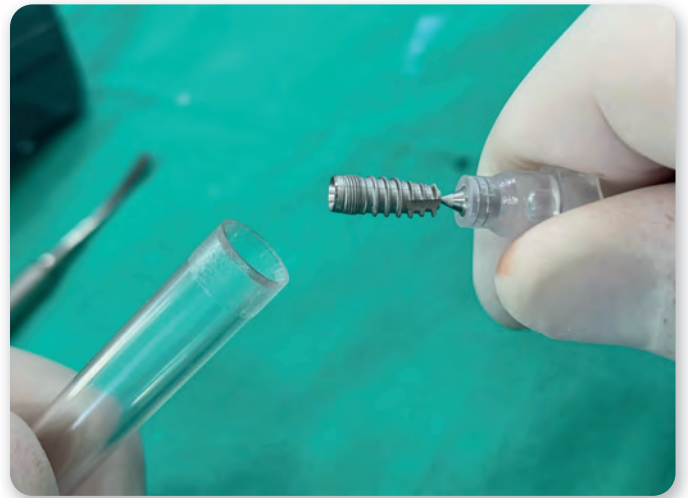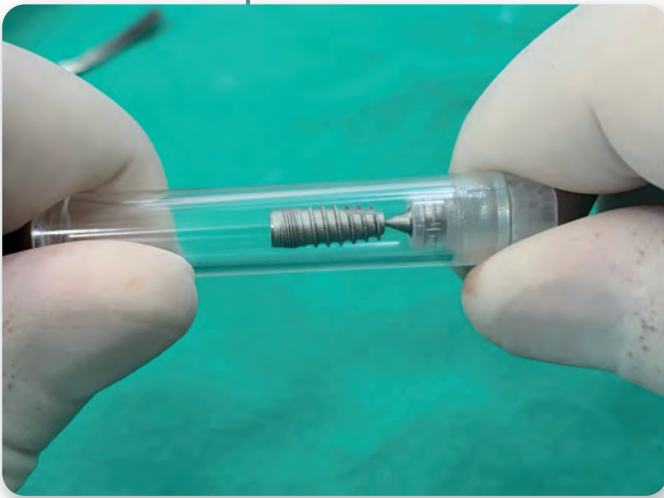29

Drill 3

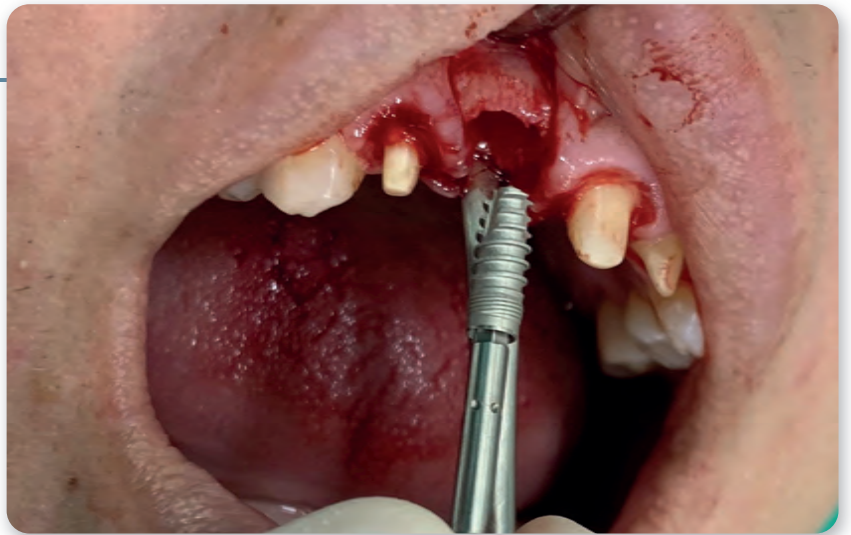
30 - 35

Implant & insertion tool



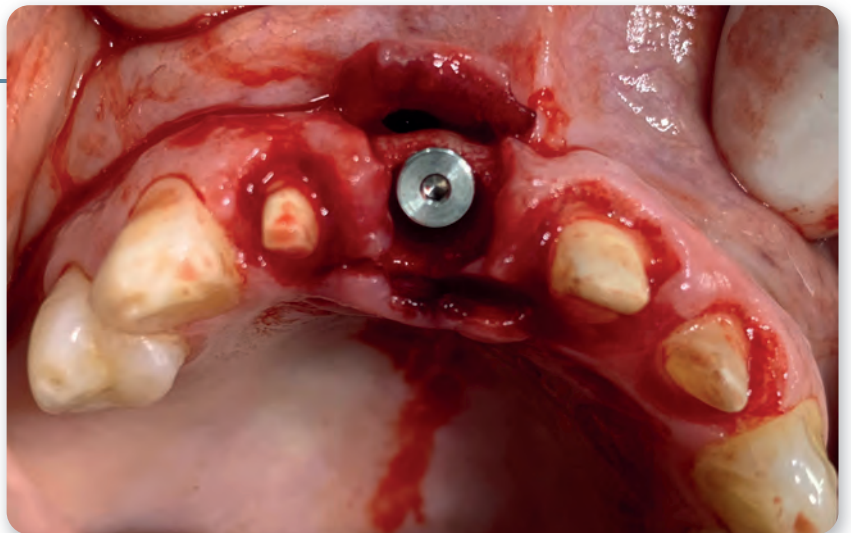
36

Implant placement



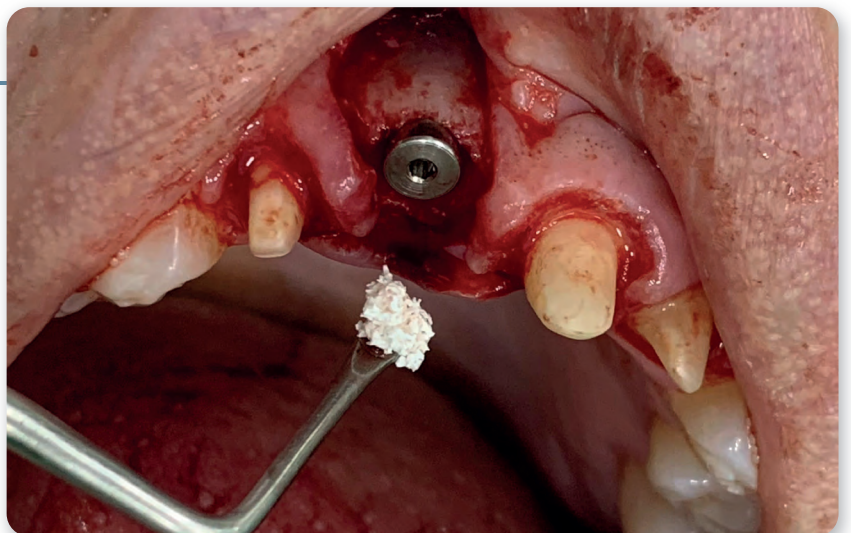
37

Gingiva former



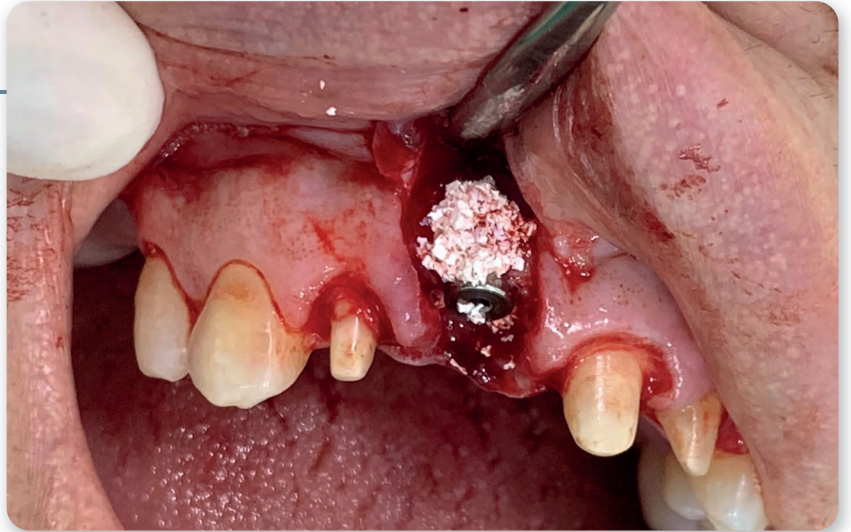38

Alveola bone grafting



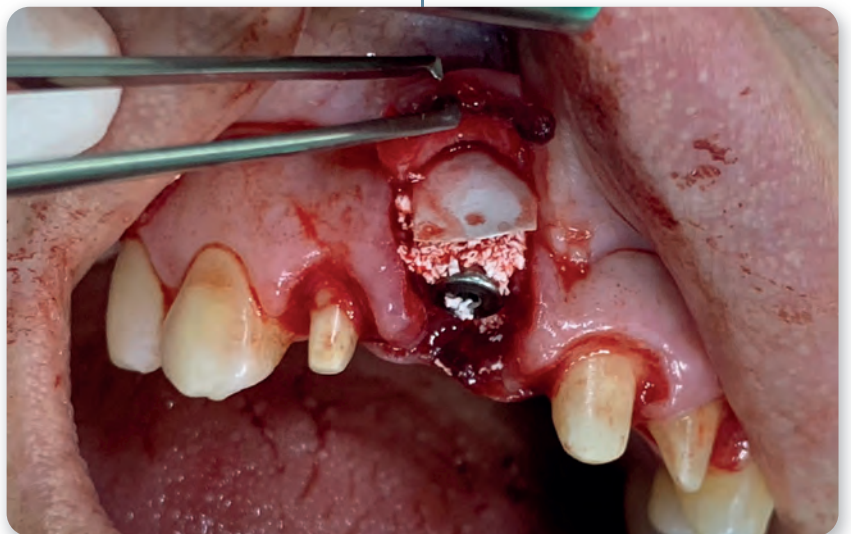
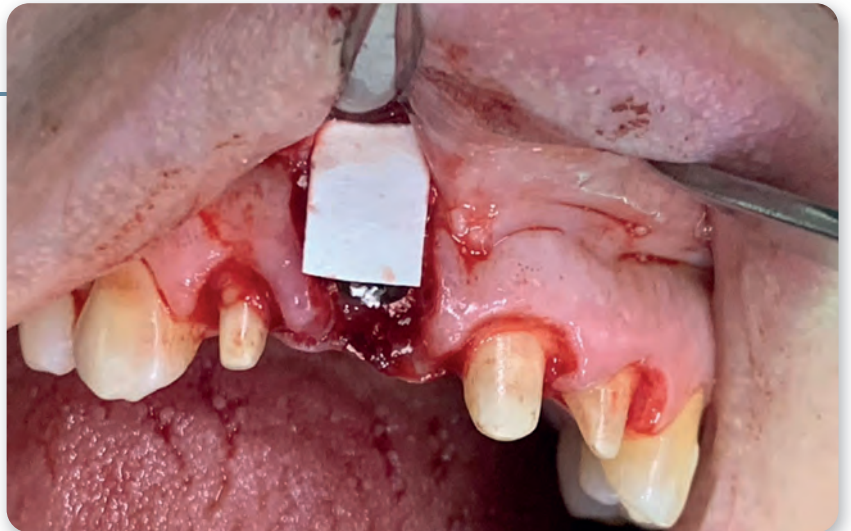
39

Bone graft contour
augmentation



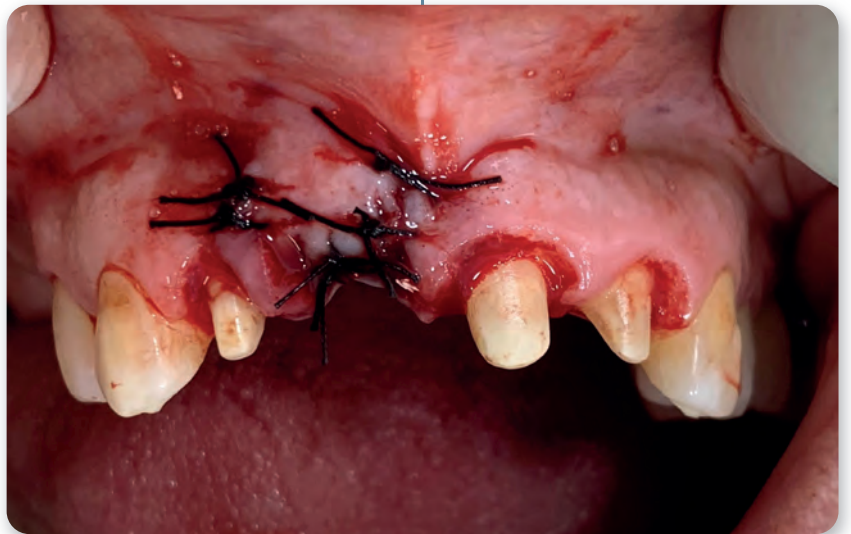
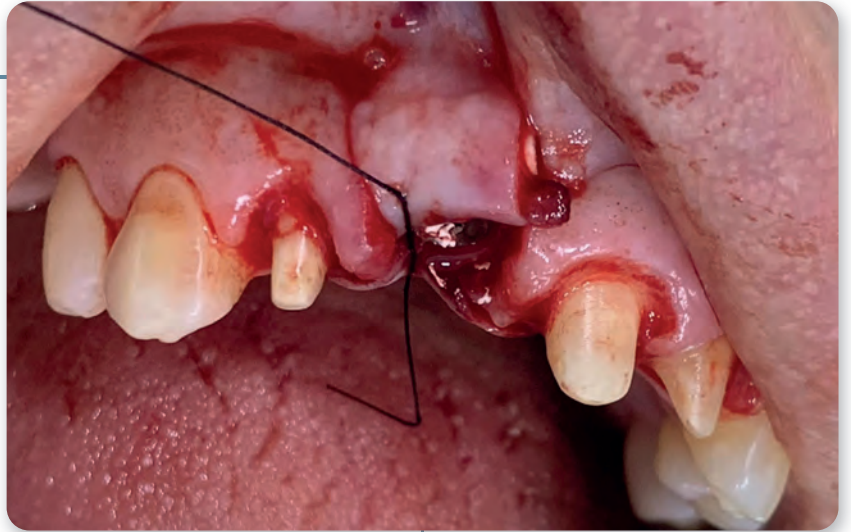
40 - 41

Protective collagen
membrane



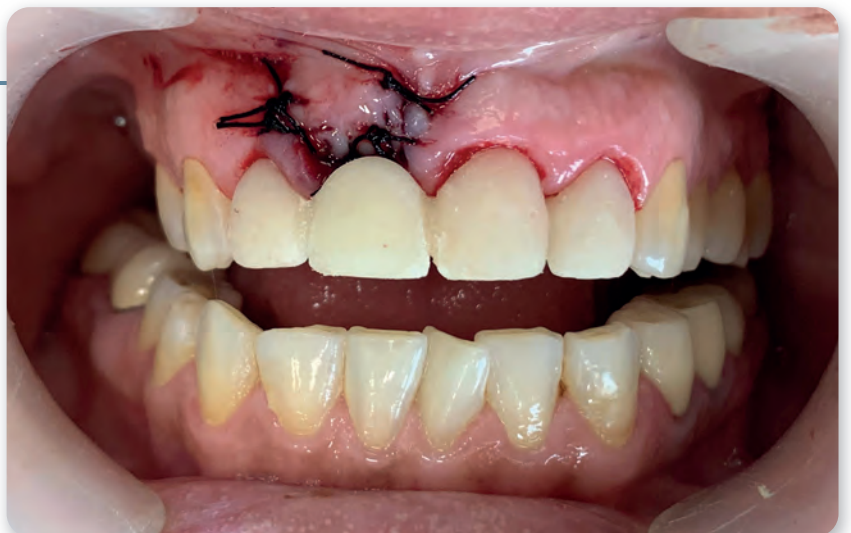42 - 43

Sutures with no tension



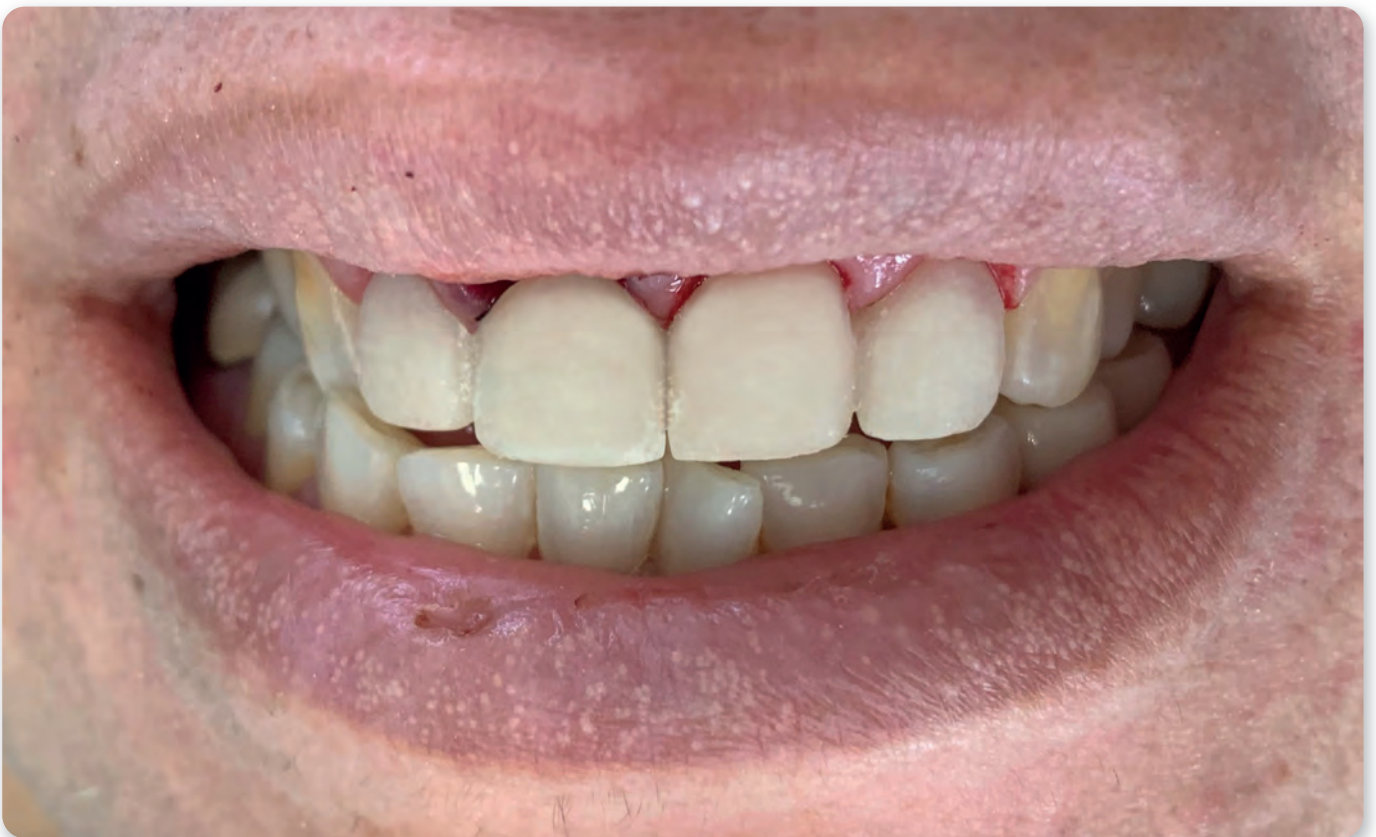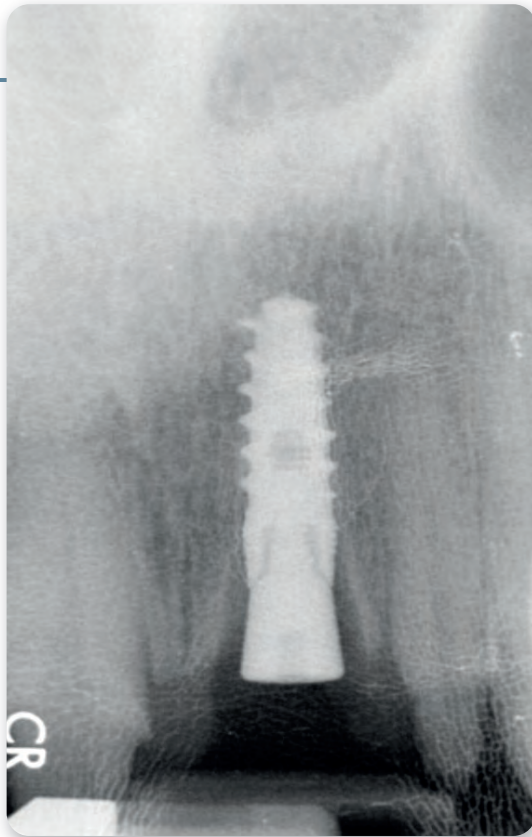
44

Temporaries cementation



45

Final X-Ray



46

End of surgical &
temporaries procedure