

## CLINICAL CASE II

---

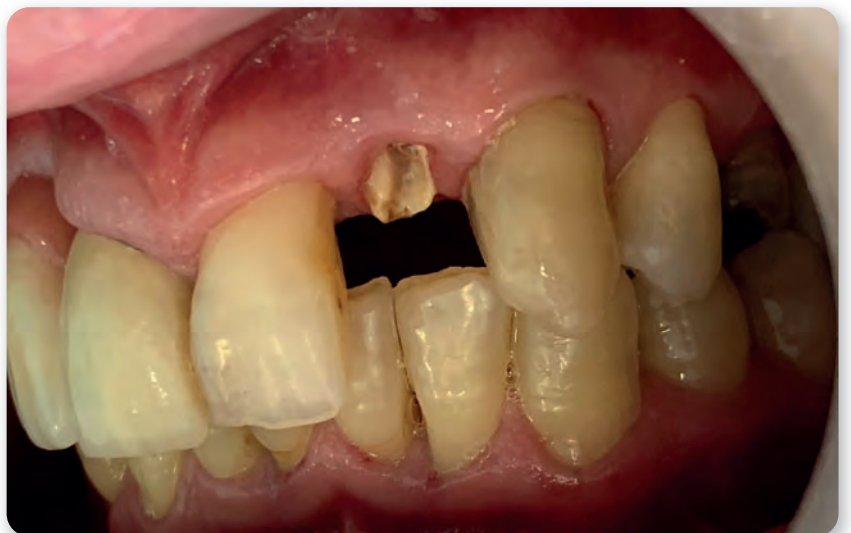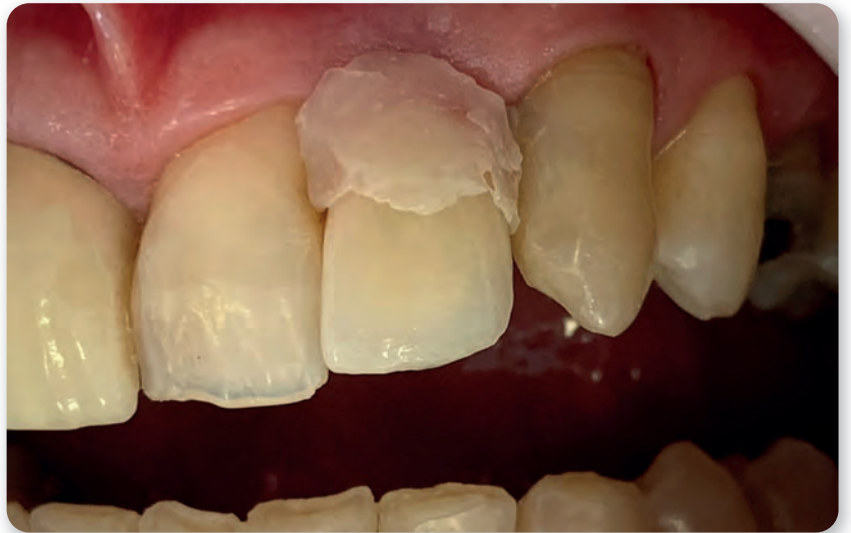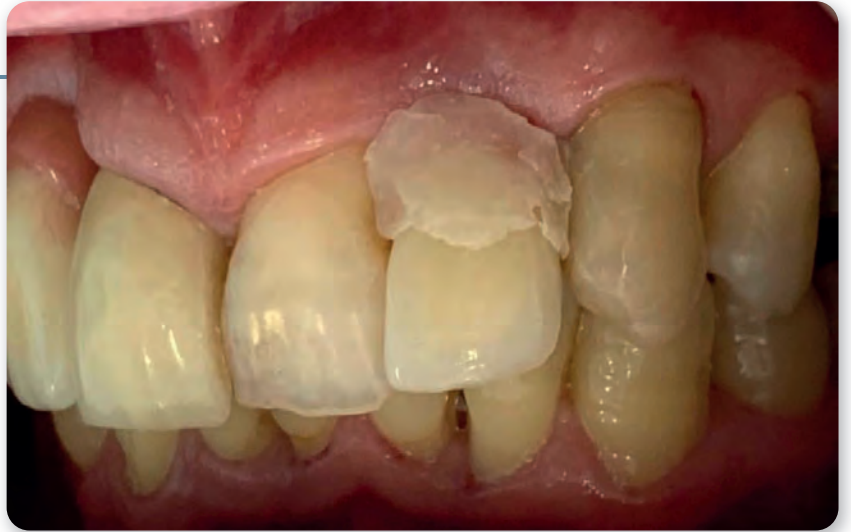### IMMEDIATE IMPLANTATION

using the Hexacone® system  
on a maxillary lateral incisor

The surgery was performed by Dr. Ralph Zarazir, using the Hexacone® system

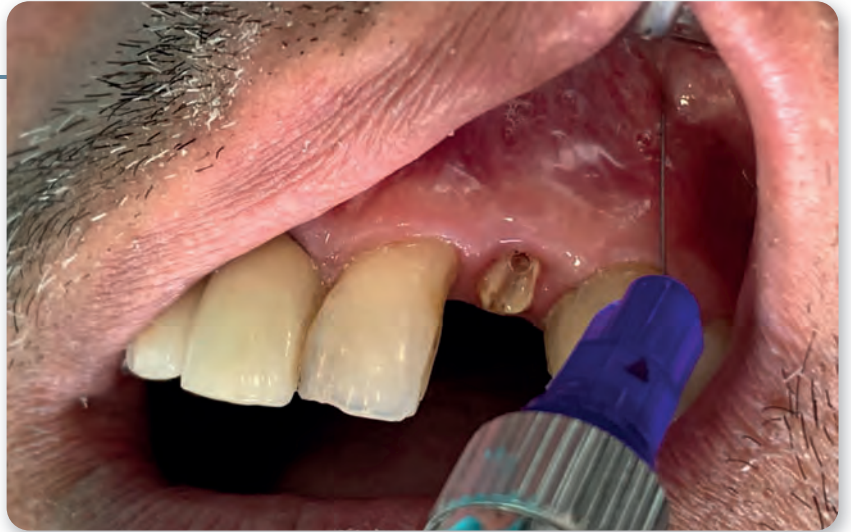1 - 3

Broken root  
Maxillary left lateral incisor



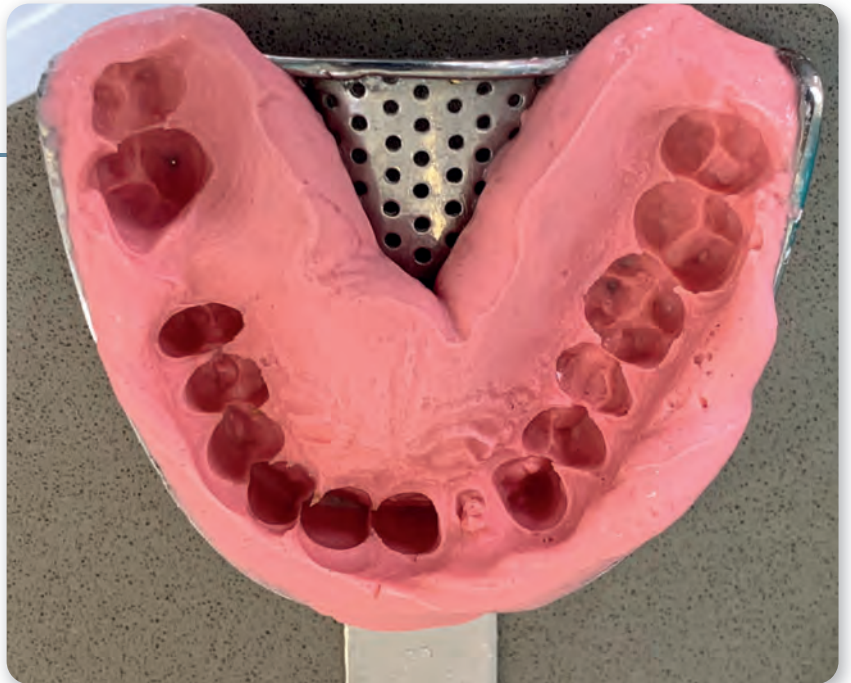
4

Local anesthetics



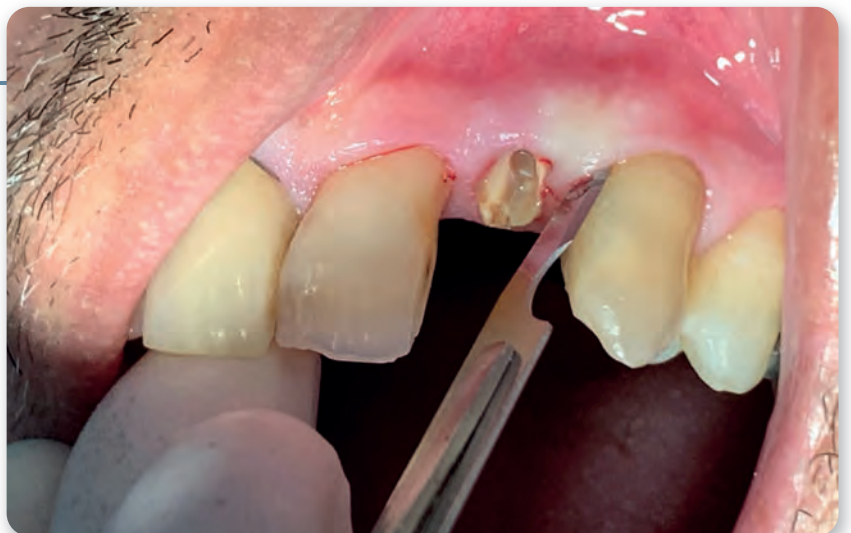5

Impression for temporary



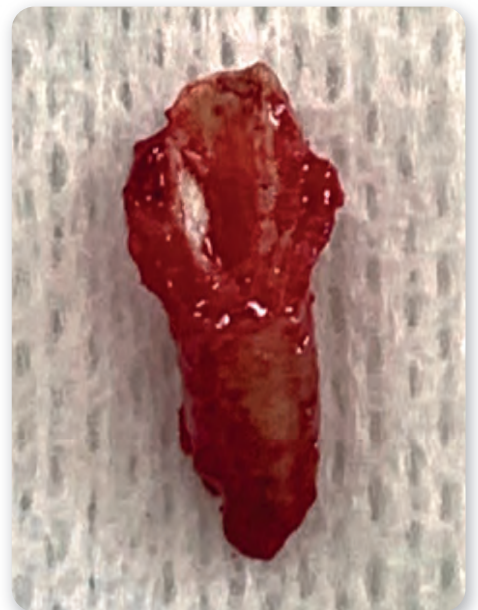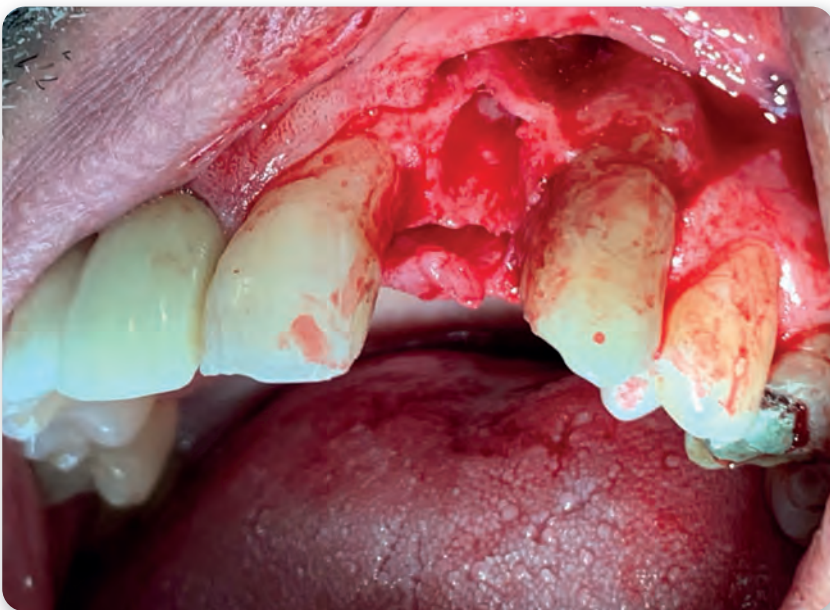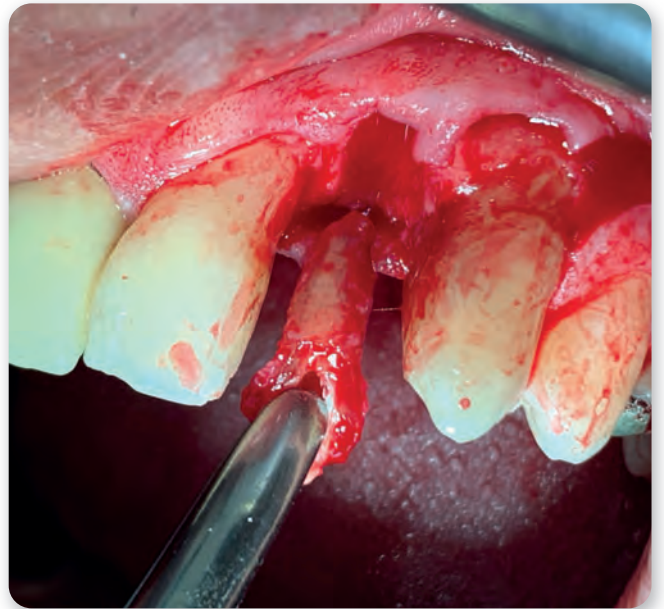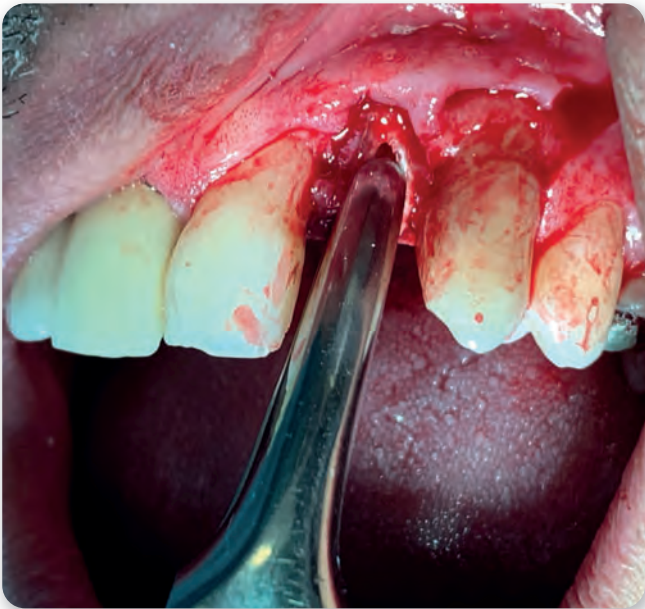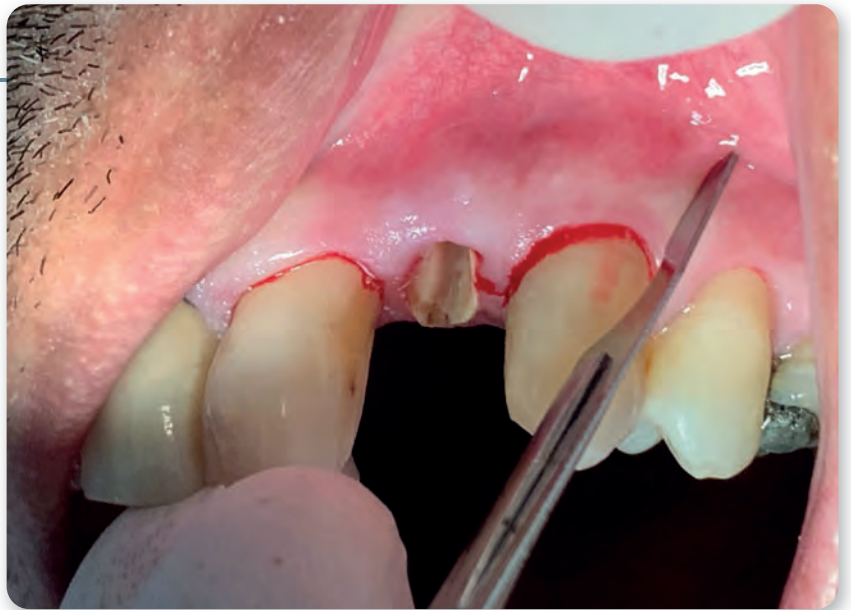6

Incision



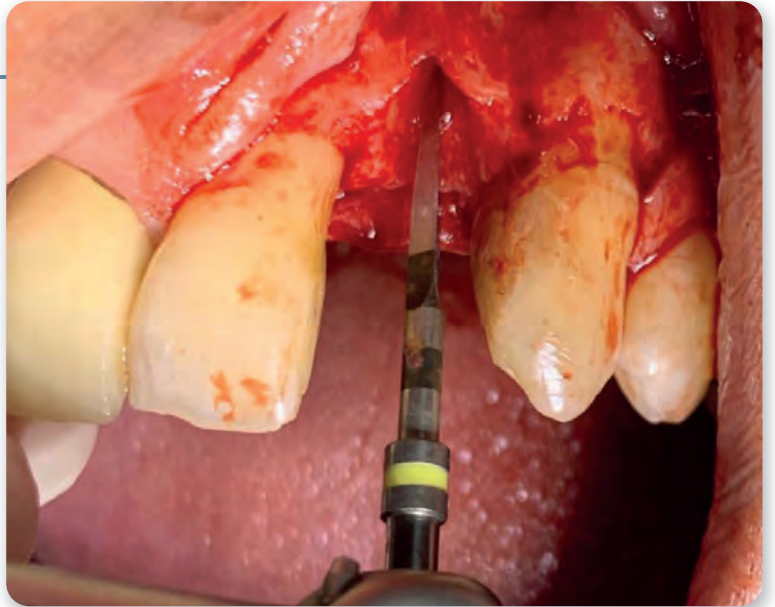
7 - 11

Flap elevation & extraction



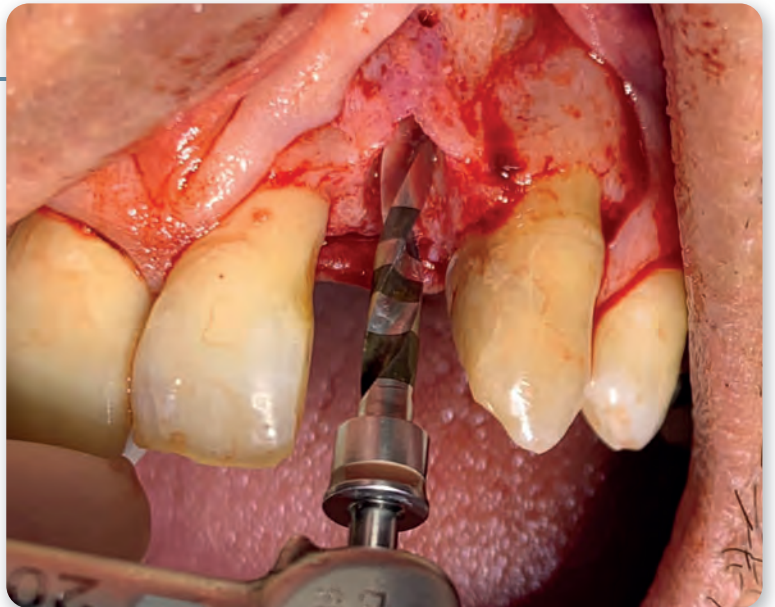
12

Pilot drill



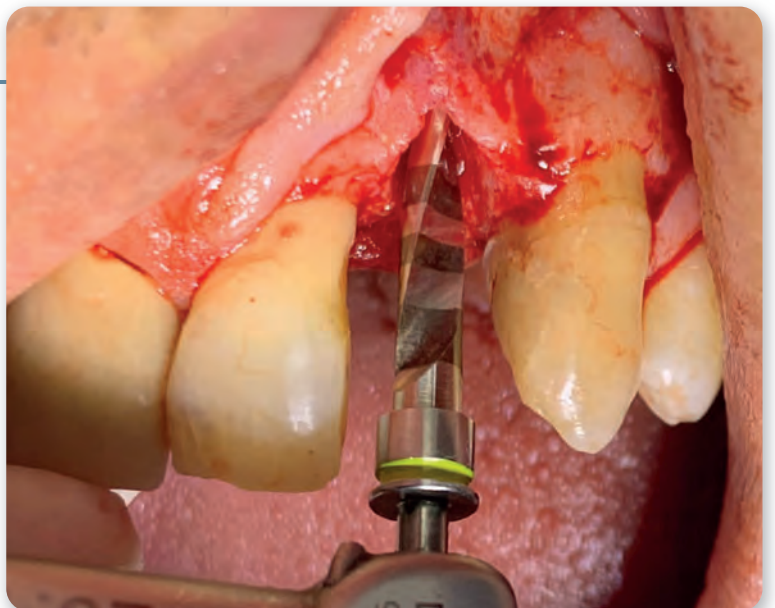
13

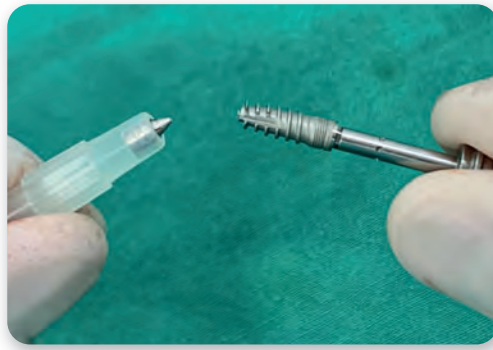
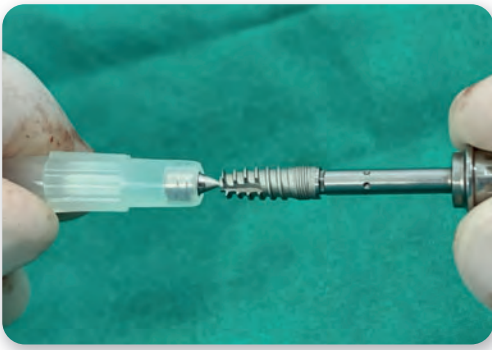Drill 1



14

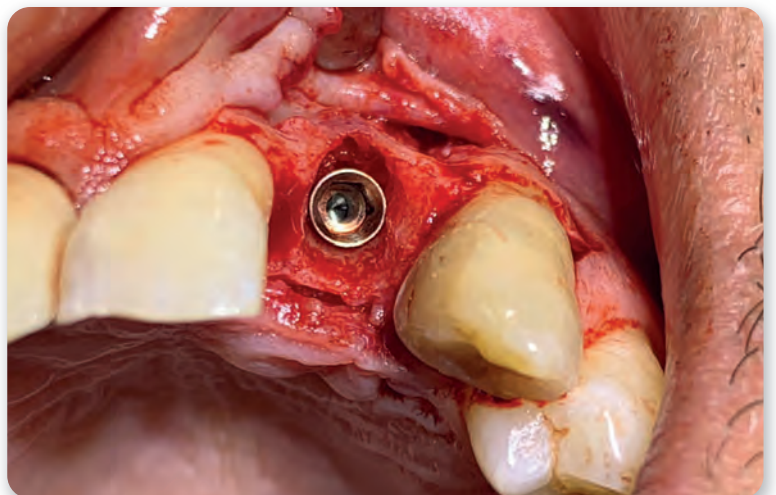
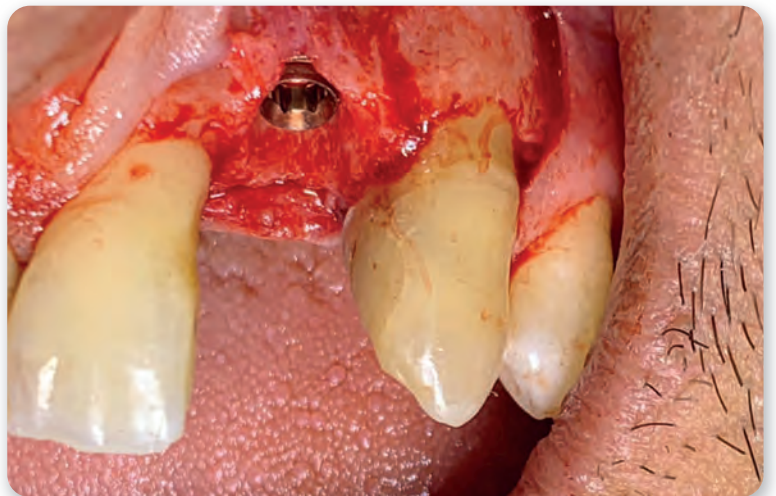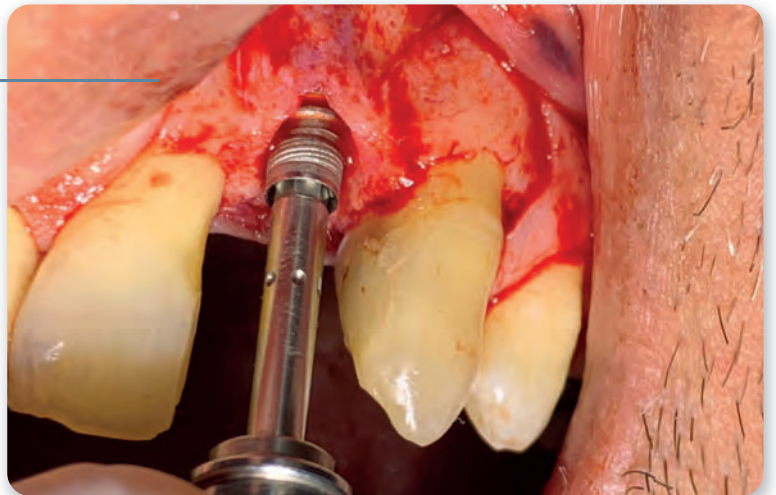
Drill 2





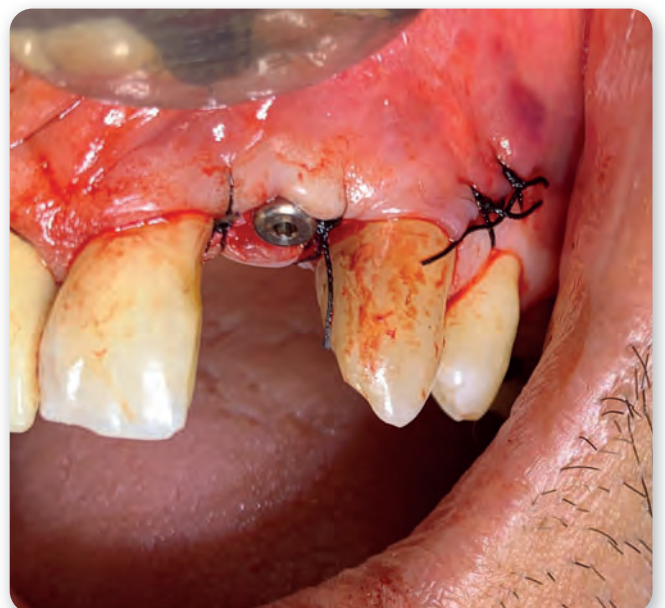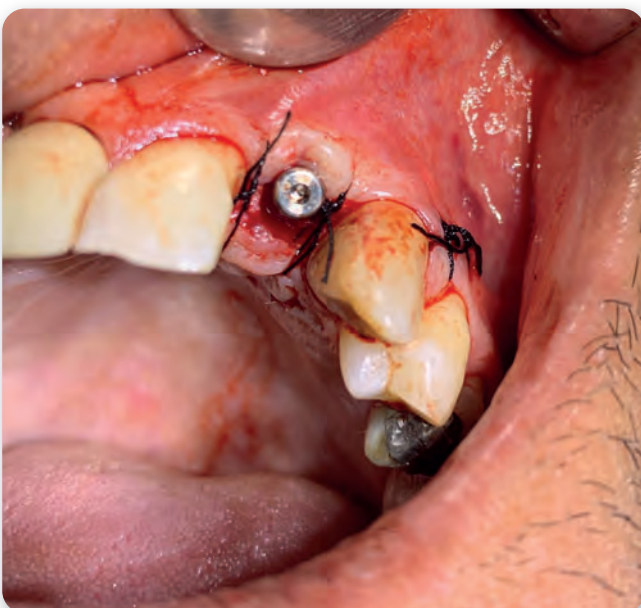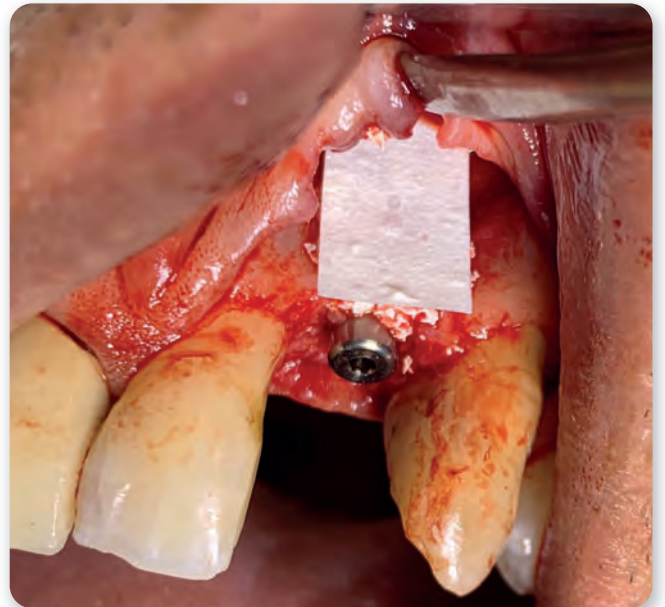
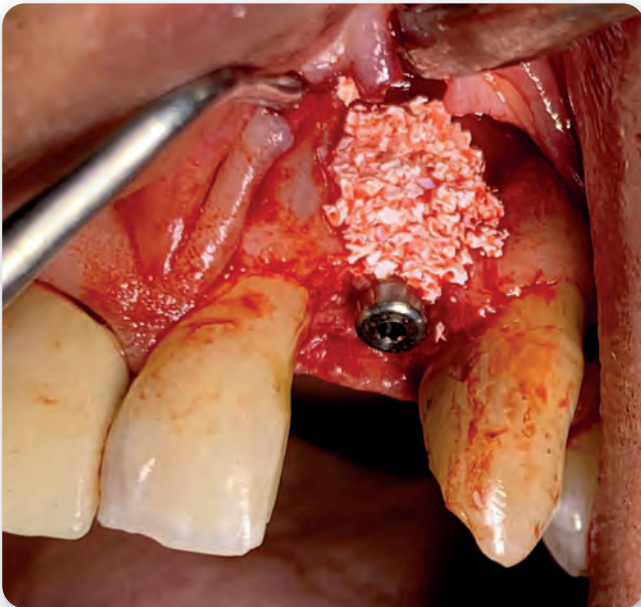
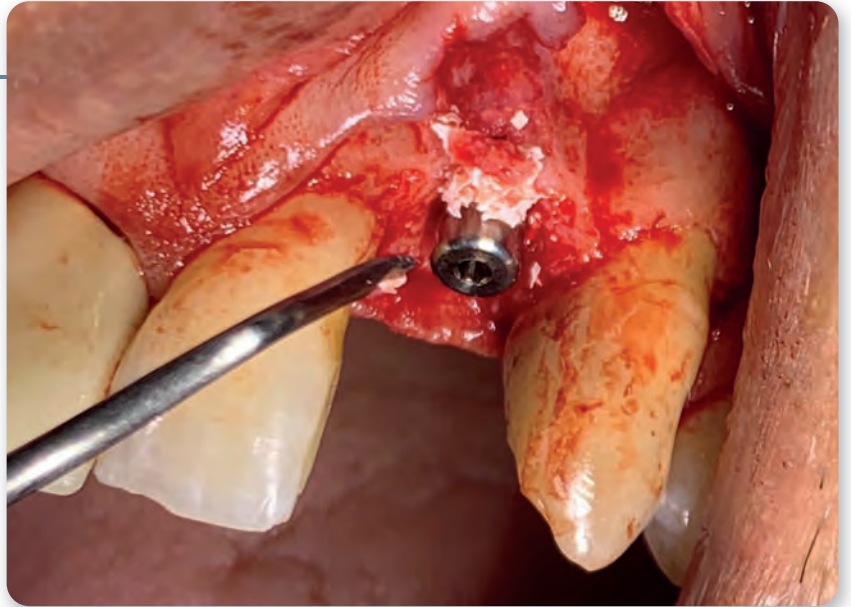
16 - 18

Implant insertion

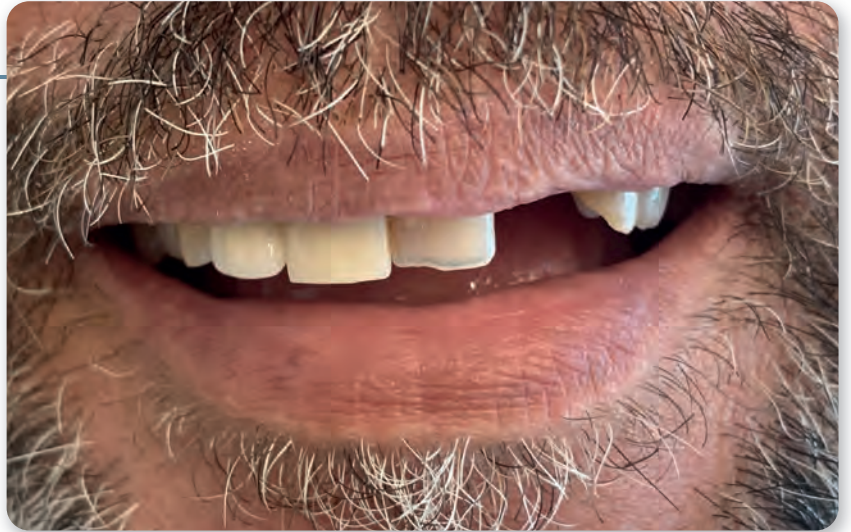

19 - 23

Bone grafting procedure

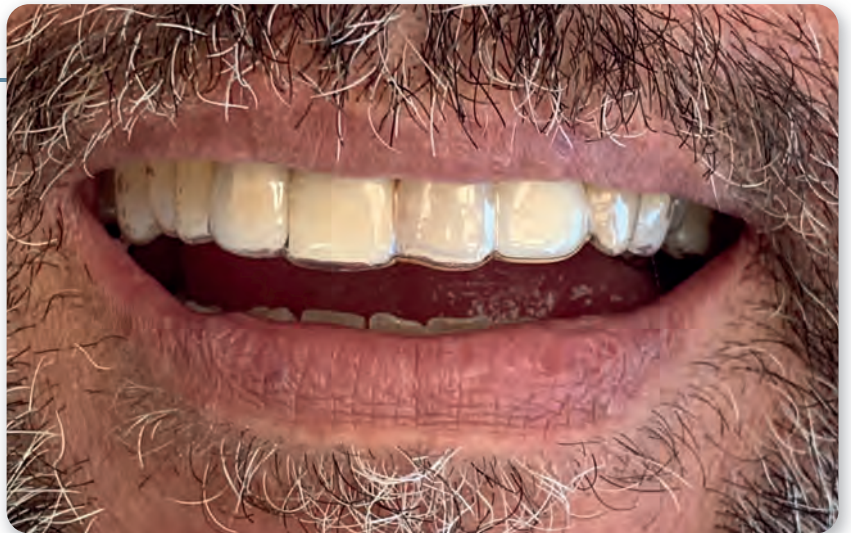

24



25

Temporary tray in place



## IMPLANT DENTISTRY



MADE SIMPLE