

CLINICAL CASE III

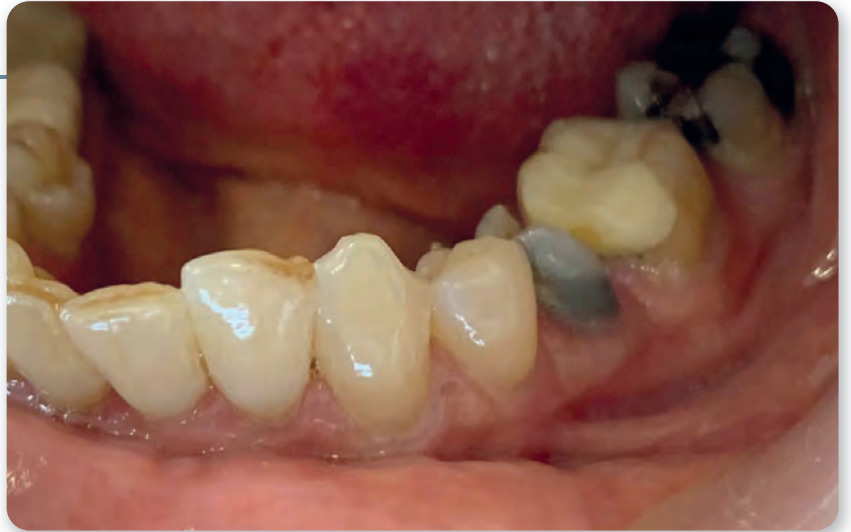IMMEDIATE IMPLANTATION

using the Hexacone® system
on a mandibular second premolar

The surgery was performed by Dr. Ralph Zarazir, using the Hexacone® system

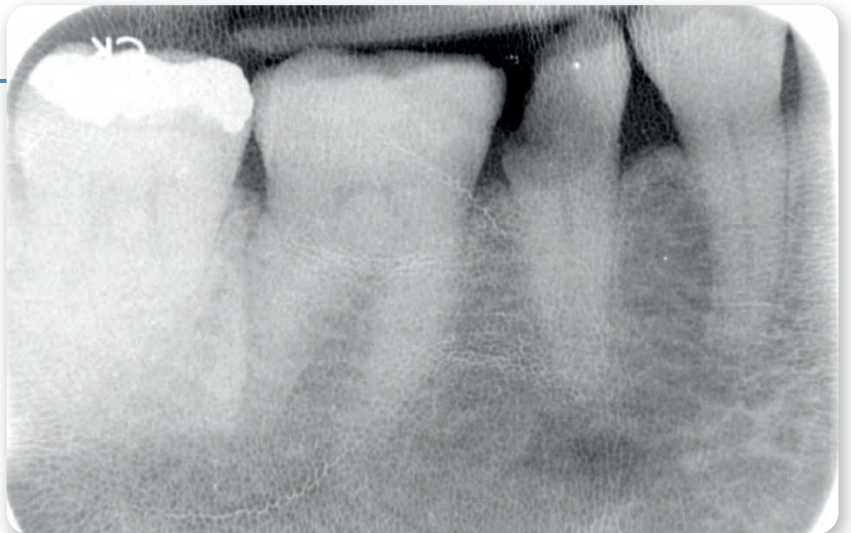
1

Deeply damaged second left mandibular molar



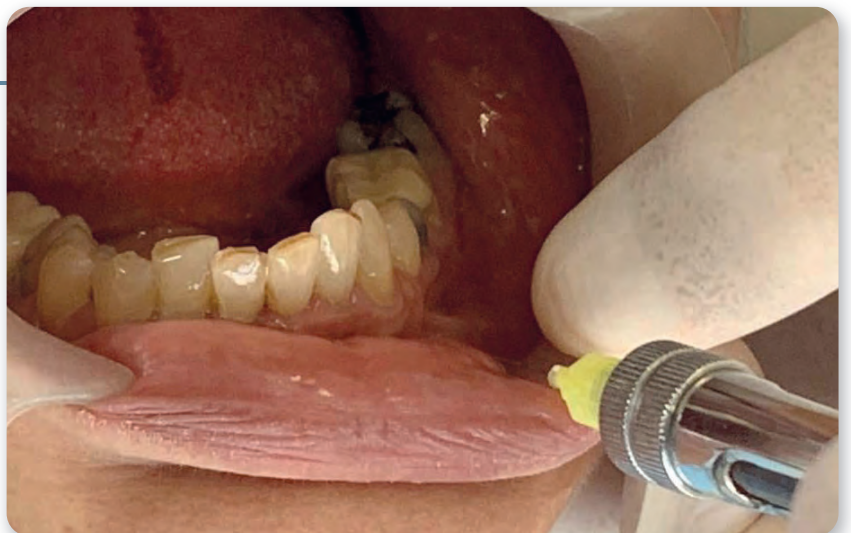2

X-ray confirmation of the clinical situation



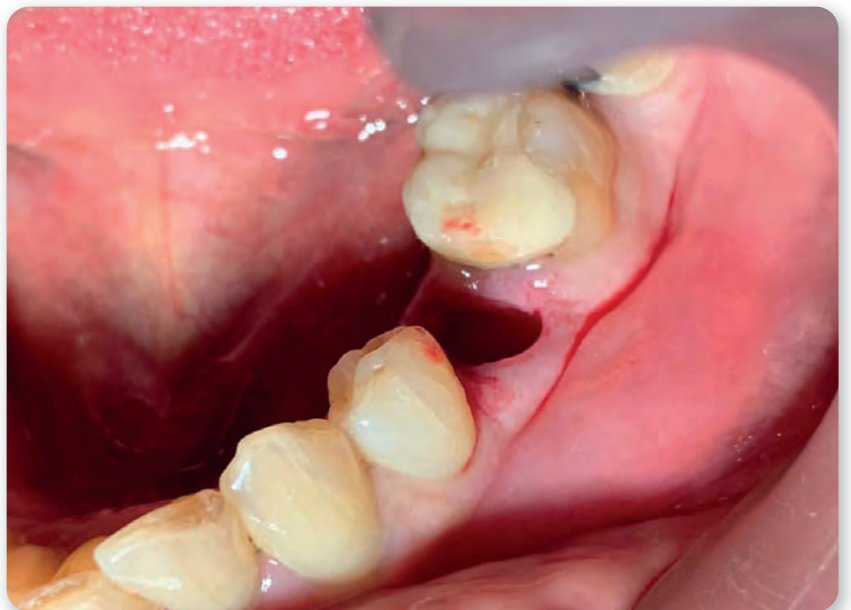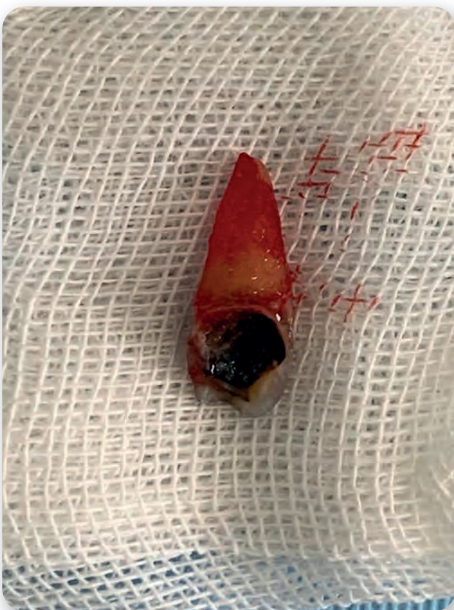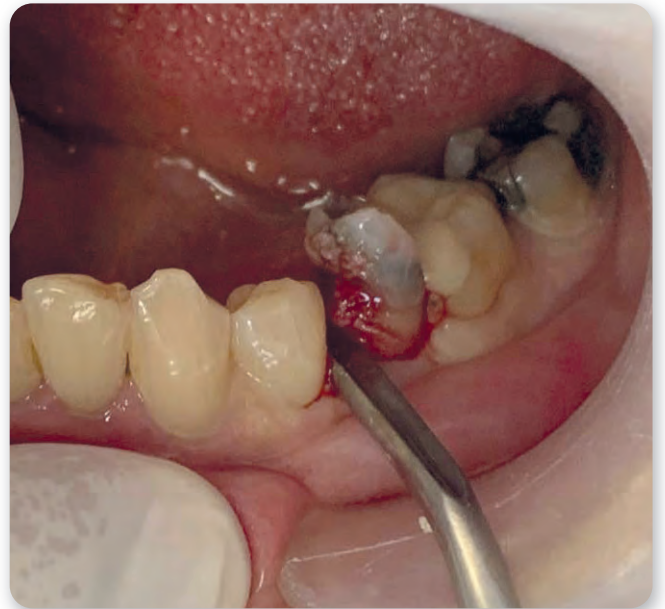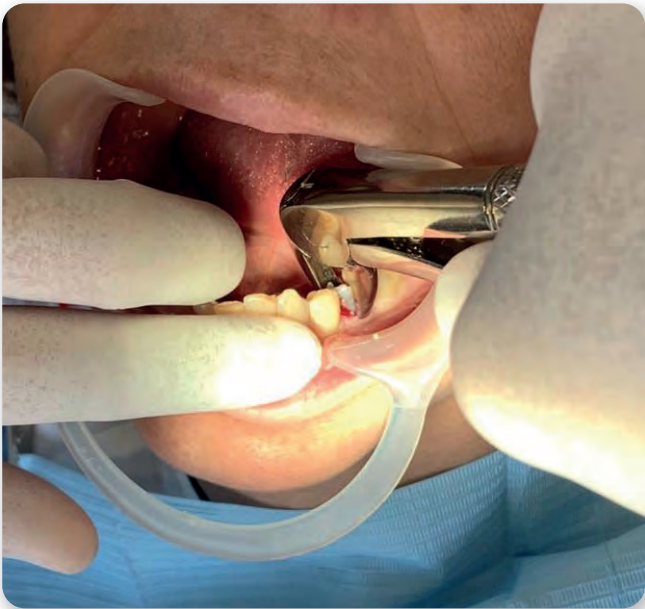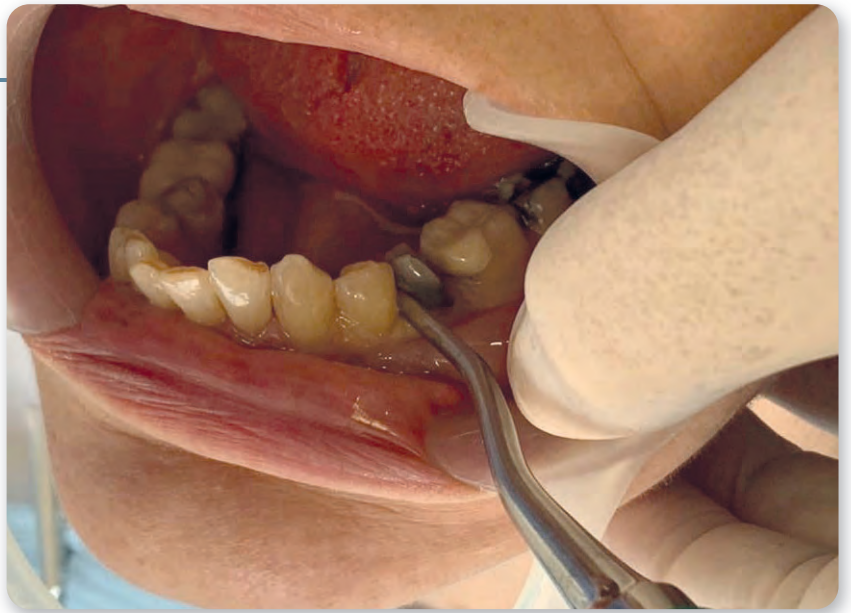4

Local anesthetics



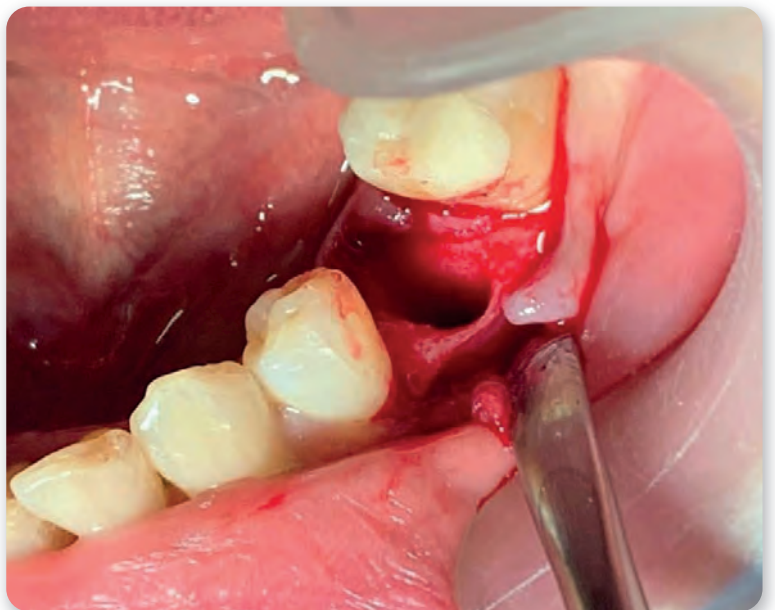
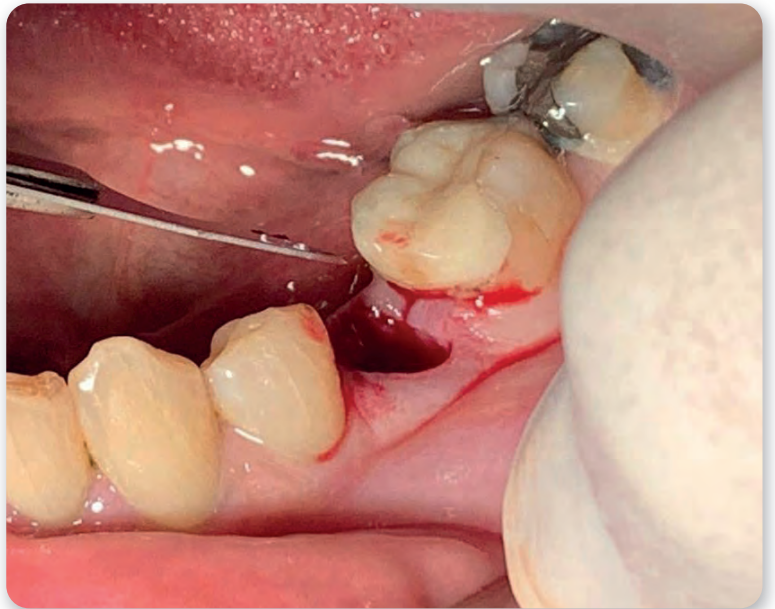
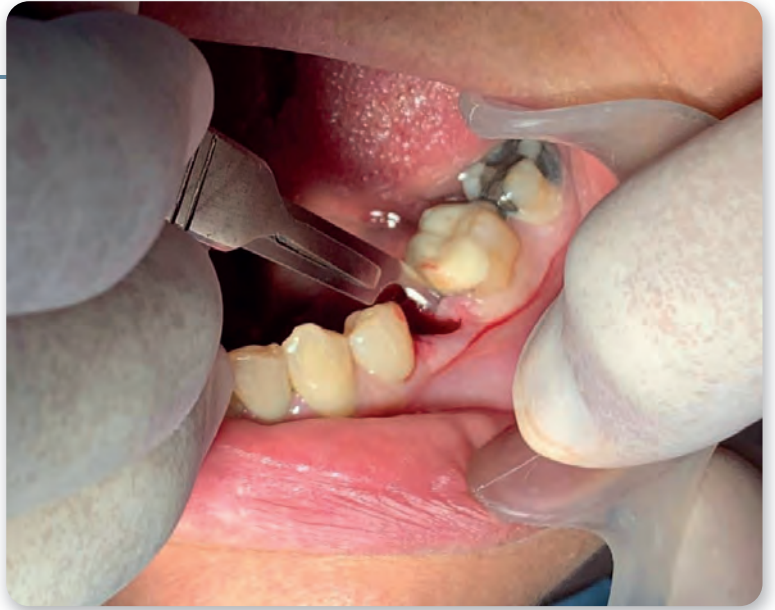5 - 9

Atraumatic tooth extraction



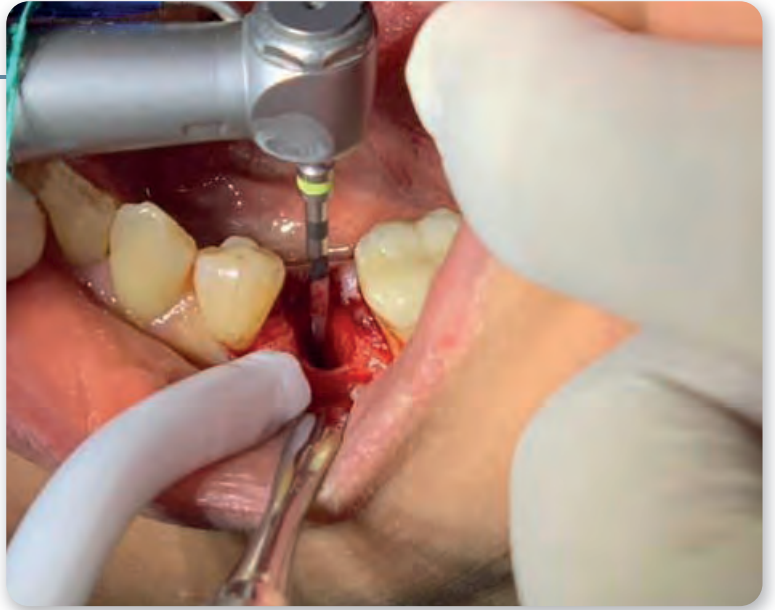10 - 12

Minimal flap elevation



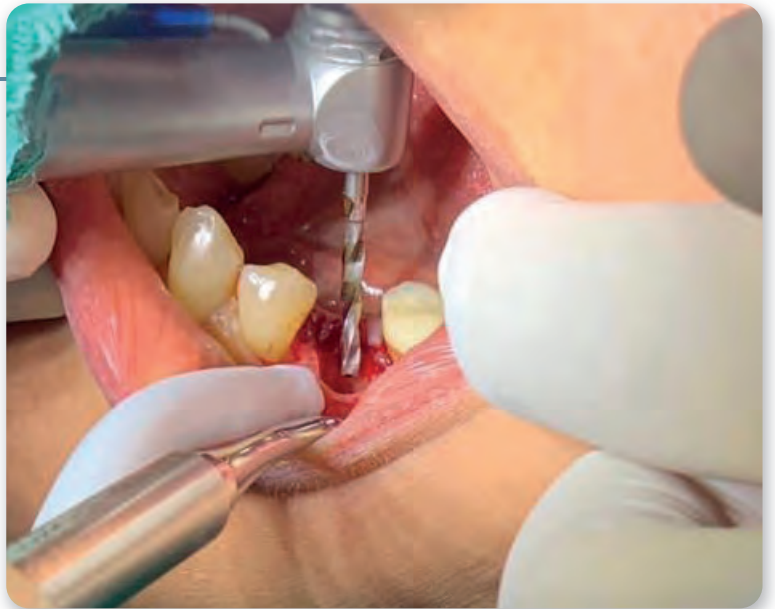13

Pilot drill



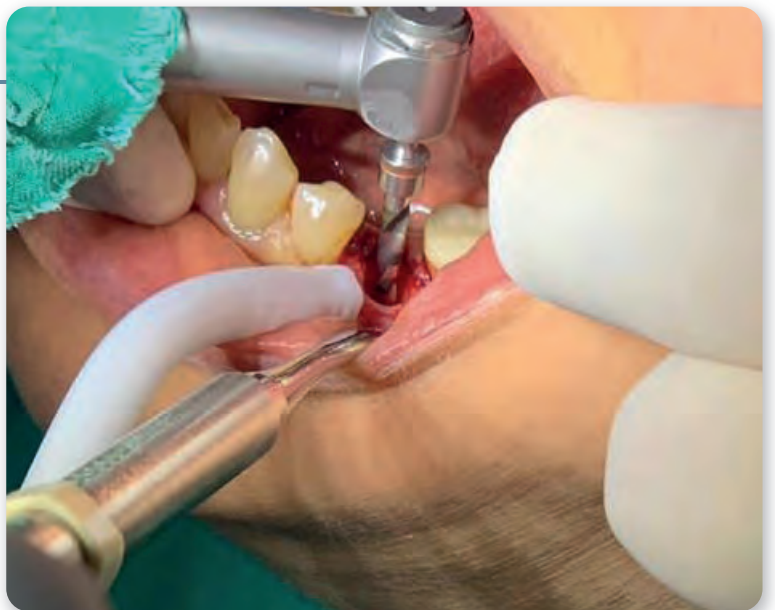14

Drill 1



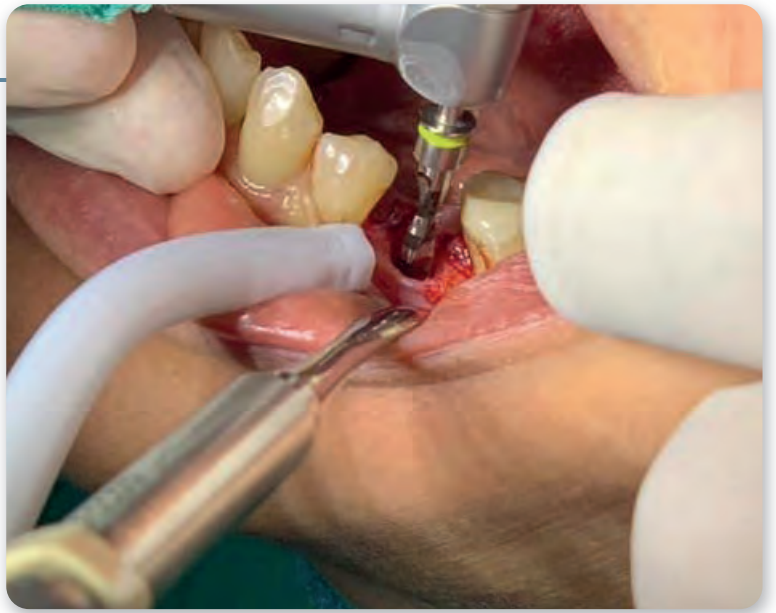
15

Drill 2




16

Drill 3



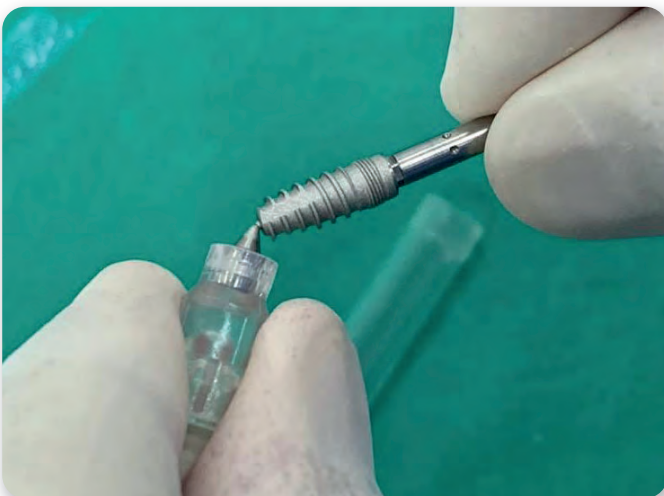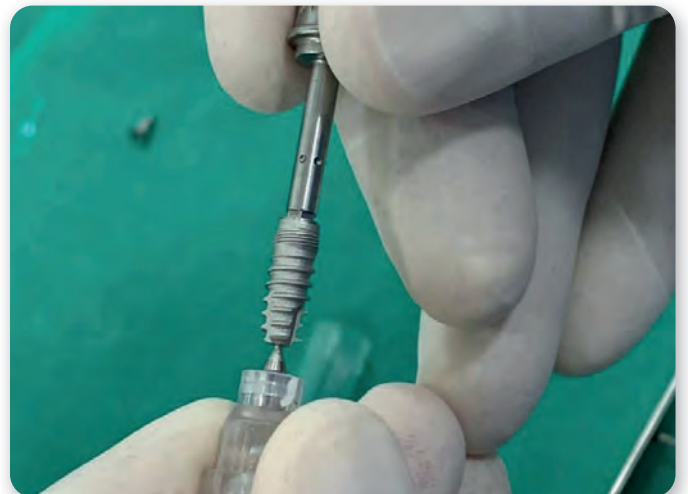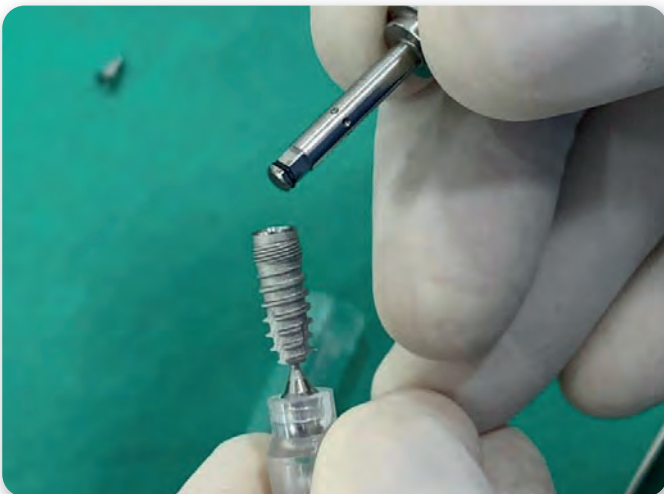
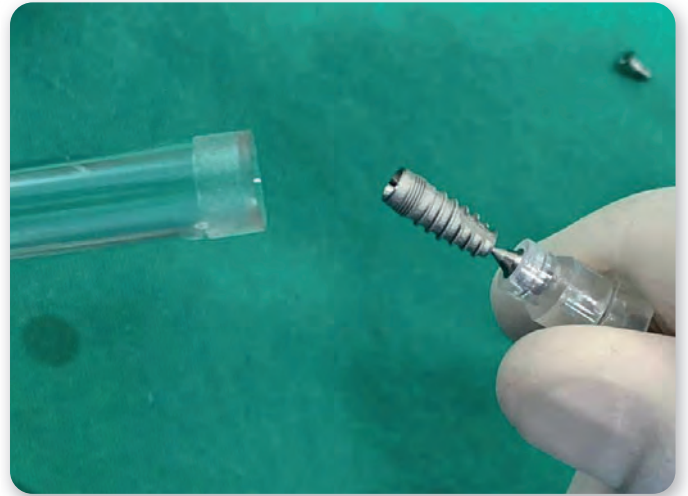
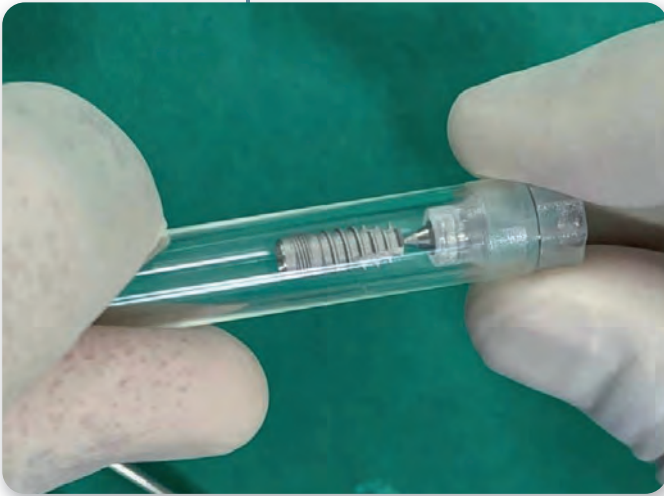IMPLANT DENTISTRY



MADE SIMPLE

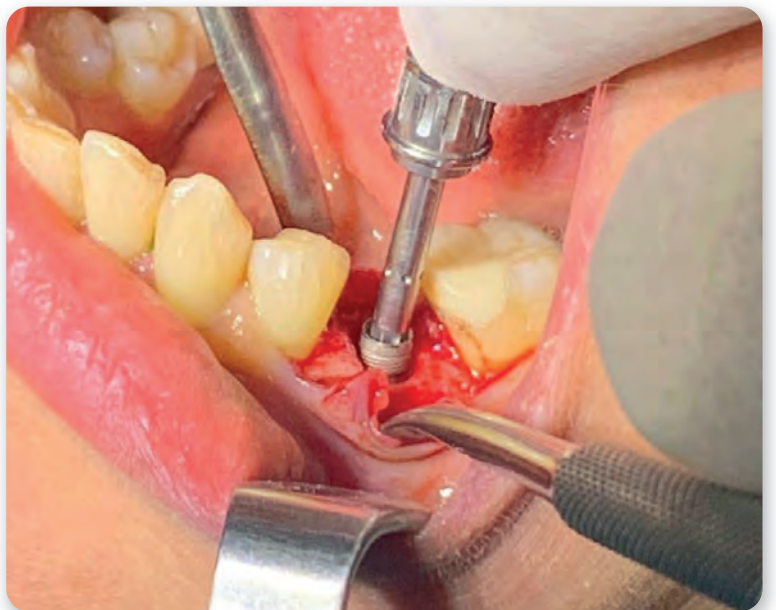
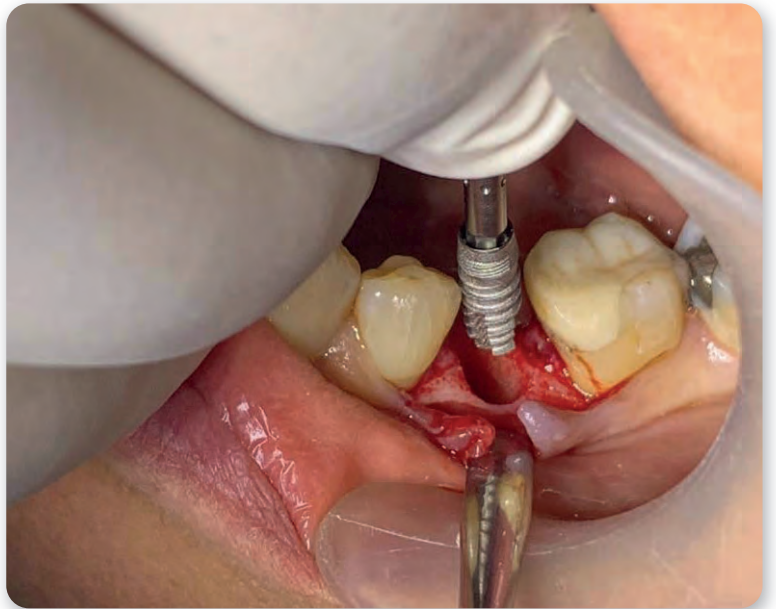
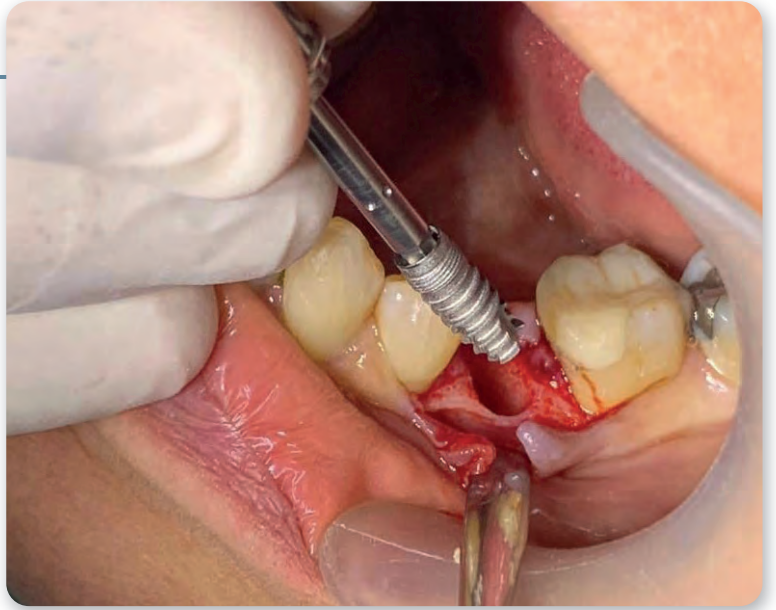
17 - 22

Implant & insertion tool



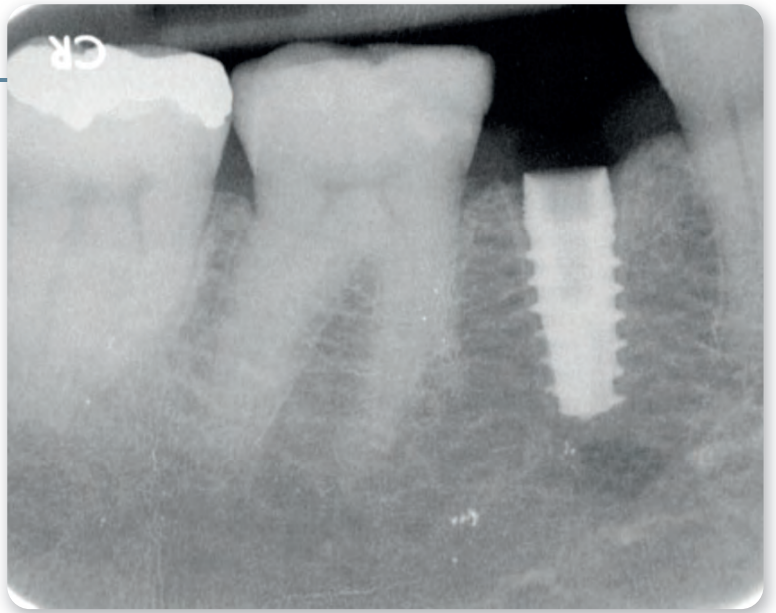
23 - 25

Implant placement



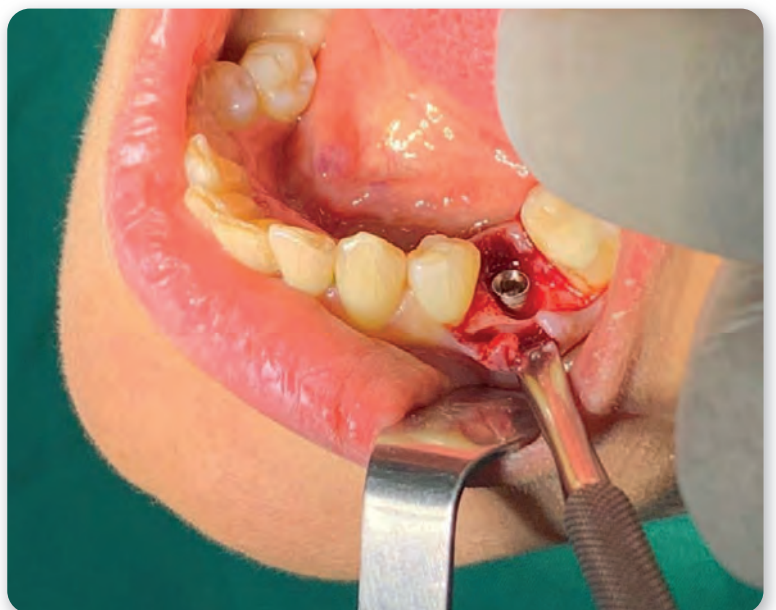
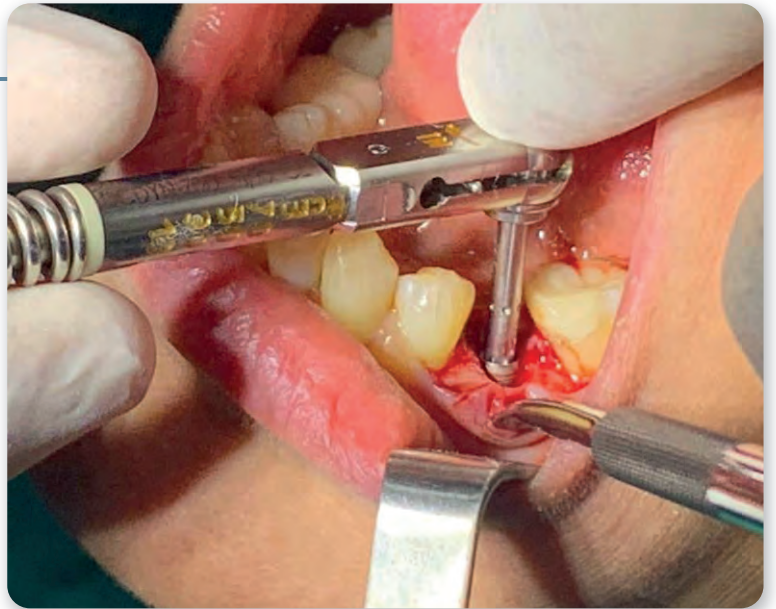
26

X-ray check -
Nerve proximity



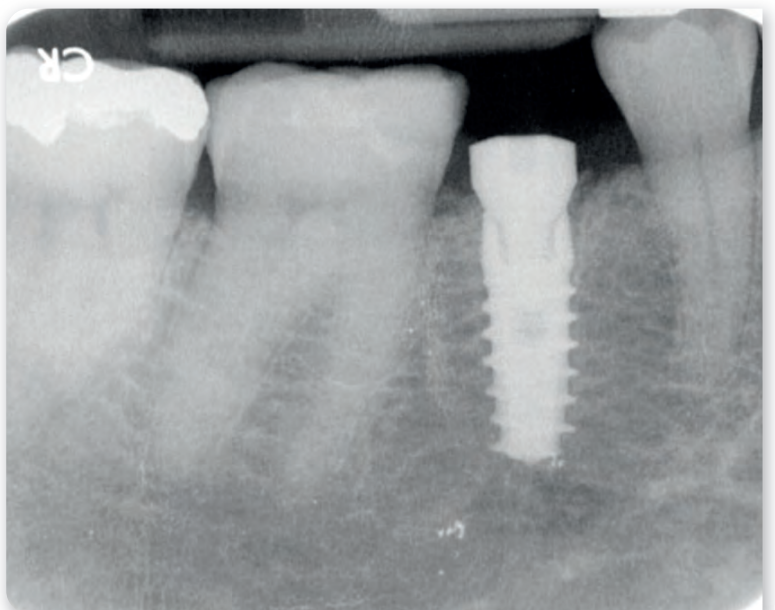
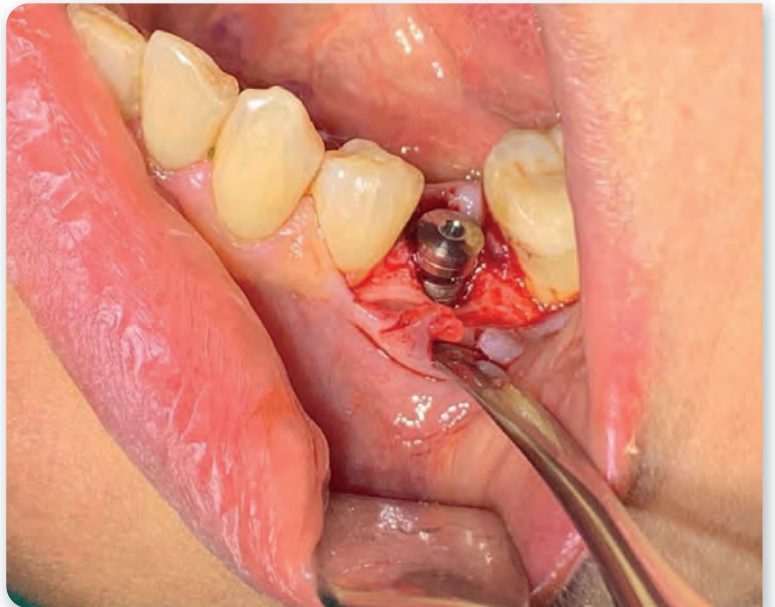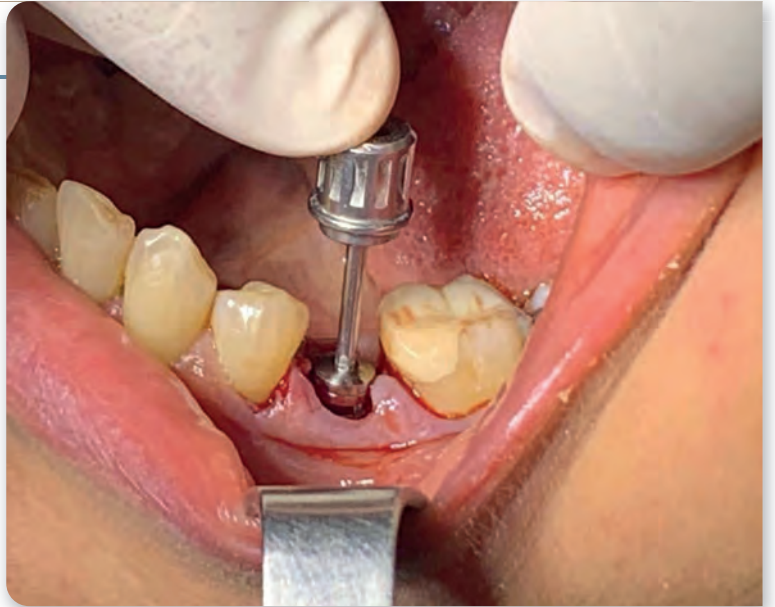27 - 28

Deeper implant insertion



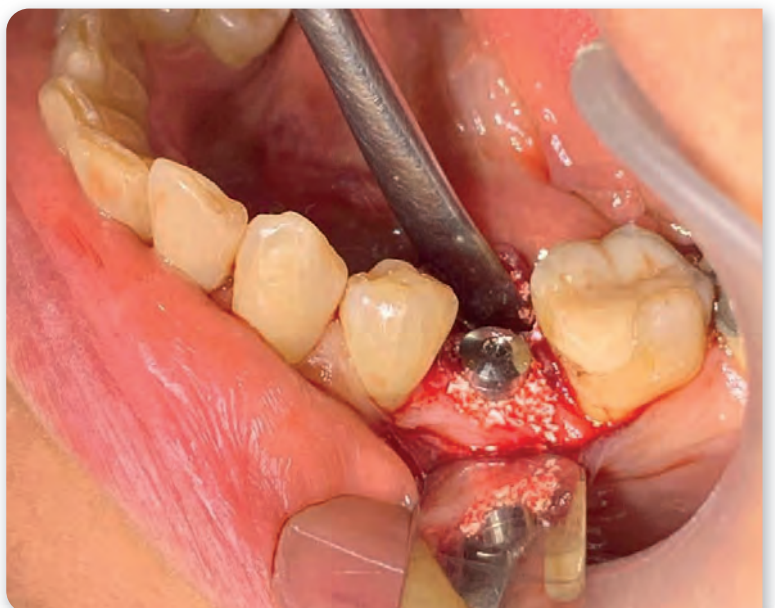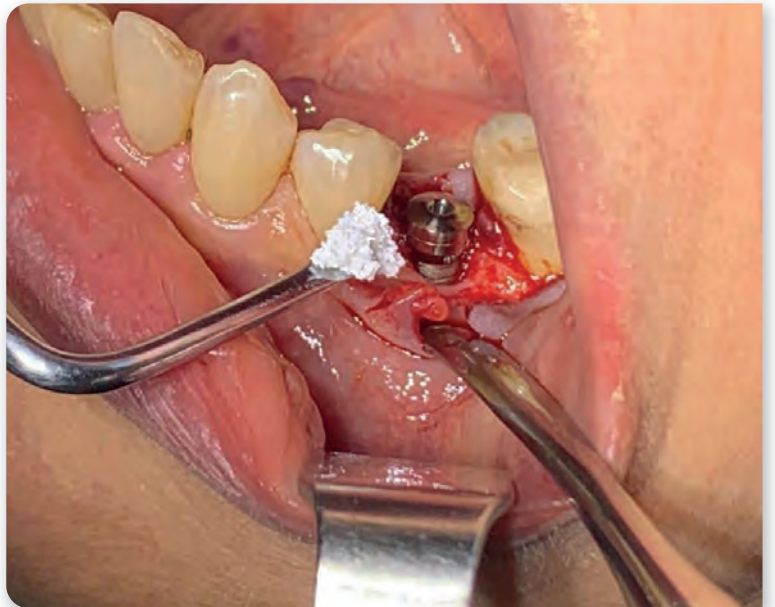
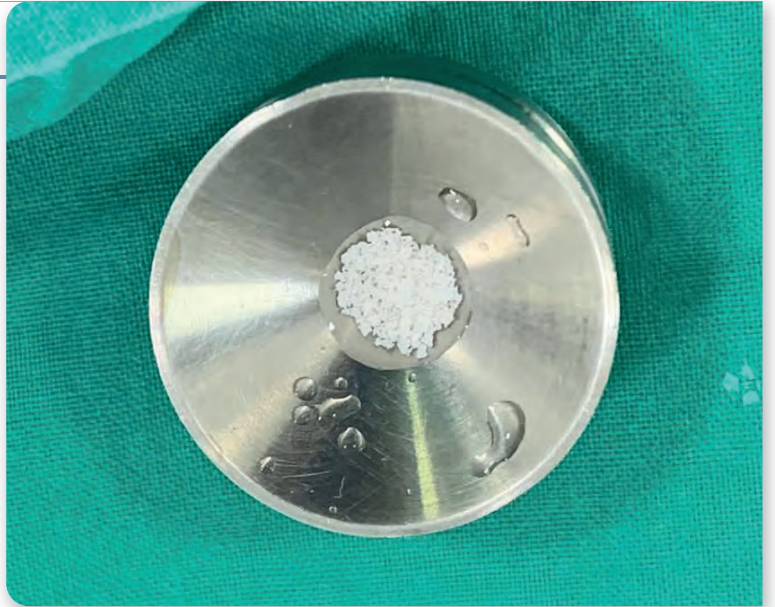
29 - 31

Gingiva former



32 - 34

Bone grafting procedure



35 - 37

Sutures with no tension

